

**THE DEVELOPMENT OF AN INTRODUCTORY E-LEARNING
MODULE ON ECHOCARDIOGRAPHY**

by

Hanin Abdullah

A thesis submitted to the Department of Biomedical and Molecular Sciences

In conformity with the requirements for
the degree of Master of Science

Queen's University

Kingston, Ontario, Canada

(February, 2012)

Copyright © Hanin Abdullah, 2012

ABSTRACT

Echocardiography, or cardiac ultrasound, is an imaging technique that has been increasingly used by multiple clinicians due to its ease of use and the valuable information that can be obtained from it. As a result, echocardiography training has been incorporated into multiple postgraduate medical programs. In addition, there have been increasing attempts to incorporate this imaging modality into the undergraduate medical curriculum. Due to the importance of this technique and its increased use, there have been multiple online resources on echocardiography developed. However, there is not a single freely accessible resource that is directed at first-time “naïve” learners. The goal of this study was to create an easy-to-access online learning module on echocardiography that can be used by first-time learners. The online resource was designed to provide an overview of the skills to be acquired during introductory level training in echocardiography. The module was developed through the Medical Education Technology unit at Queen’s University to allow access by all medical faculty and students associated with this institution. The content and images of the module were evaluated by a group of twelve first year medical students who had no prior experience with echocardiography. This group found that the content coverage was sufficient for their limited knowledge in echocardiography and that the images used were sufficiently-labelled to enhance their learning. Also, the plastinated sectional heart images, which were included, were well-accepted and the students found them helpful for interpreting echocardiographic images. In addition, the module was assessed by a group of cardiologists who are involved in echocardiography training and research at Kingston General Hospital. There was consensus from this group about the usefulness and effectiveness of this introductory echocardiography learning module.

ACKNOWLEDGMENTS

I would like to thank Dr. Raveen S. Pal for her incredible guidance and support throughout the time course of this project. Her insight and dedication to the field of cardiology generally, and echocardiography specifically, have inspired the birth of this project. I would also like to extend my thanks to my supervisor Dr. Ronald Eastel for believing in this project and allowing it to reach the final stages in a directed manner.

I would also like to extend warm thanks to the director of the Master's program in Anatomical Sciences, Dr. Les MacKenzie, for taking the time to contribute his wisdom and for always having an open and receiving mind in matters relating to this project. I also extend further thanks to Dr.'s Stephen Pang and Conrad Reifel for their help and intellectual input.

I would like to thank Dr. Xiaohu Yan, Ms. Lynel Jackson, Mr. Rick Hunt and Mr. Earl Donaldson for dedicating time and effort to this project. I would also like to extend appreciation to the staff in the Division of Cardiology at Kingston General Hospital for their patience and to the staff in the Department of Biomedical and Molecular Sciences (Formerly Anatomy and Cell Biology) for their help including Marilyn McAuley, Janet LeSarge, Anita Lister and Jan McGraa.

Last, but certainly not least, I would like to dedicate my deepest thanks to my family and friends for their endless support and understanding. I am grateful for their generous patience and care.

TABLE OF CONTENTS

Abstract.....	ii
Acknowledgements.....	iii
Table of contents.....	iv
List of figures.....	vi
List of tables	viii
Abbreviations.....	ix
Chapter 1 Introduction	1
1.1. Echocardiography in clinical practice	1
1.2. Echocardiography training in postgraduate medical education	2
1.3. Ultrasound in undergraduate medical education.....	3
1.4. Online learning.....	5
1.5. Objectives and hypothesis.....	6
1.6. Background information.....	7
1.6.1. Echocardiography theory.....	7
1.6.2. Echocardiographic examination.....	7
1.6.3. Patient position.....	8
1.6.4. Transducer placement and position.....	9
1.6.5. Image orientation.....	10
1.6.6. Standard tomographic views.....	11
1.6.7. Assessment of heart function using echocardiography.....	15
Chapter 2 Methods.....	33
2.1. Selection of content.....	33
2.2. Echocardiographic videos and images.....	34
2.3. Plastinated heart images	35
2.4. Anatomical illustrations.....	36
2.5. Summary tables.....	36
2.6. Preliminary survey: Assessment of content and images.....	37
2.7. Online “IntroToEcho” Module.....	37
2.8. Evaluation of the module.....	38
Chapter 3 Results	42
3.1. Content coverage.....	42

3.2. Image quality.....	42
3.3. Plastinated heart specimens.....	43
3.4. Additional remarks	43
3.5. Online "IntroToEcho" module on MEdTech.....	43
3.5.1. Overview	44
3.5.2. Introduction to echocardiography	44
3.5.3. Ultrasound physics	44
3.5.4. Review of heart anatomy	45
3.5.5. Image acquisition	45
3.5.6. Standard tomographic views	46
3.5.7. Assessment of heart function	46
3.5.8. Credits.....	47
Chapter 4 Discussion	57
4.1. Content	57
4.2. Image quality	58
4.3. Plastinated heart specimens	58
4.4. Online "IntroToEcho" module	59
4.5. Future considerations	60
4.6. Conclusion	61
References.....	62
Appendix A.....	66

LIST OF FIGURES

Figure 1 Anatomical illustrations of heart morphology and location	17
Figure 2 Common acoustic windows in echocardiography	18
Figure 3 Main standard acoustic planes in echocardiography	19
Figure 4 Parasternal long-axis view (PS LAX)	20
Figure 5 Parasternal right ventricular inflow tract view (PS RVIT)	21
Figure 6 Parasternal short-axis view at the aortic valve (PS SAX Aortic valve).....	22
Figure 7 Parasternal short-axis view at the mitral valve (PS SAX Mitral)	23
Figure 8 Parasternal short-axis view at the mid-ventricle (PS SAX Mid-ventricle)	24
Figure 9 Parasternal short-axis view at the apex (PS SAX Apex)	25
Figure 10 Apical four-chamber view (Apical 4C).....	26
Figure 11 Apical five-chamber view (Apical 5C)	27
Figure 12 Apical two-chamber view (Apical 2C)	28
Figure 13 Apical three-chamber/long-axis view (Apical 3C/LAX).....	29
Figure 14 Subcostal four-chamber view (Subcostal 4C)	30
Figure 15 Subcostal short-axis view (Subcostal SAX).....	31
Figure 16 Echocardiographic image of the suprasternal long-axis of the aortic arch (Suprasternal).....	32
Figure 17 Summary tables for long-axis (LAX) and parasternal right ventricular inflow tract (PS RVIT) planes.....	39
Figure 18 Summary tables for short-axis (SAX) planes at the levels of aortic valve, mitral valve and mid-ventricle, respectively	40
Figure 19 Summary tables for four-chamber (4C), two-chamber (2C) and suprasternal long-axis of aortic arch planes	41
Figure 20 The layout of the IntroToEcho online module as it appears on MEdTech Central	48
Figure 21 A screenshot of the “introduction to echocardiography” folder	49
Figure 22 A screenshot of the “ultrasound physics” folder	50
Figure 23 A screenshot of the “review of heart anatomy” folder	51
Figure 24 The five surfaces of the heart	52
Figure 25 A screenshot of the “image acquisition” folder.....	53
Figure 26 A screenshot of the “standard tomographic views” folder	54

Figure 27 A screenshot of the top portion of the “parasternal long-axis” subfolder 55
Figure 28 A screenshot of the “assessment of heart function” folder 56

LIST OF TABLES

Table 1 Evaluation of image quality by 12 respondents from the preliminary survey	43
--	----

ABBREVIATIONS

2C	Two-chamber
3C	Three-chamber
4C	Four-chamber
5C	Five-chamber
ASE.....	American Society of Echocardiography
AVI.....	Audio Video Interleave
CVD.....	Cardiovascular disease
CT	Computed tomography
HTML.....	Hypertext Markup Language
IVC	Inferior vena cava
JPG	Joint Photographic Experts Group
KGH	Kingston General Hospital
kHz	Kilo-Hertz
LAX.....	Long-axis
MEdTech	Medical Education Technology Unit
M4V.....	Moving Picture Experts Group – 4 Video
PNG.....	Portable Network Graphics
PS.....	Parasternal
RVIT.....	Right ventricular inflow tract
SAX	Short-axis
SWF.....	Shockwave Flash
TEE.....	Trans-esophageal echocardiography
TTE.....	Trans-thoracic echocardiography
URL.....	Uniform Resource Locator
US.....	Ultrasound

CHAPTER 1

INTRODUCTION

Cardiovascular disease (CVD), also known as heart disease, is reported by Health Canada as the leading cause of death in Canada [1]. According to the Public Health Agency of Canada the total number of deaths due to CVD so far this year is 71,557 deaths (last updated October 25, 2011), which comprises 45.7% of all deaths caused by chronic disease this year (Total = 156,578) [2]. Moreover, CVD is also the main cause of hospitalization in Canada (excluding pregnancy and childbirth) making up 17% of all hospitalizations during fiscal year 2005/06 [3]. Health Canada reports that CVD imposes the greatest burden on Canada's National Health Care System, with more costs than any other disease [1].

In cardiology when heart disease is suspected, the first diagnostic test to be ordered is ultrasound imaging [4]. Cardiac ultrasound, also known as echocardiography, is the most widely used diagnostic technique for the examination of cardiovascular anatomy and function [5]. Echocardiography produces high-quality images that can be used to obtain valuable information to make an accurate diagnosis [6]. Moreover, echocardiography is ideal for serial (or repeated) examination to track changes because it is non-invasive, painless, requires little patient preparation and has no known side effects [5]. The time-effectiveness of ultrasound examination, including echocardiography, and the cost-effectiveness of ultrasound systems [5, 7] together make ultrasound the technique of choice.

1.1. Echocardiography in clinical practice

The ease of use and interpretation of echocardiograms coupled with the valuable information that can be obtained from an echocardiographic exam have collectively led to the widespread use of this imaging modality in medical diagnosis. Moreover, recent advances in

ultrasound technology have led to further expansion of its use within the medical field. When compared to cart US systems, the newer laptop-sized US systems are relatively inexpensive and can produce high quality digital images [8]. They are also user-friendly and thus can be used by multiple clinicians, such as primary care physicians [8]. Further miniaturization of US systems led to the birth of the phone-sized hand-held US machines which are readily available, portable and can produce high-quality images [9]. These have been used for screening heart disease and abdominal aortic aneurysm [10, 11]. Ultrasound adds a “visual” component to the stethoscope, thus providing more information than the latter more traditional medical device. Therefore, it is now believed that ultrasound, including cardiac, will soon be incorporated as part of routine physical examination [9].

Consequently, regardless of the specialty that they choose following undergraduate medical education, medical students will be exposed to ultrasound to some extent [12]. It is therefore imperative to gain an understanding of the possibilities and limitations of this expanding medical technique to be able to make a decision about its suitability for patient care and management [5]. Yet, advances in technology of US have outpaced training of prospective operators [13]. Therefore, there has been increasing effort to incorporate echocardiography specifically, and US generally, into undergraduate medical curricula as well as into more postgraduate medical programs.

1.2. Echocardiography training in postgraduate medical education

As a result of the widespread use of this imaging modality, echocardiography training has been integrated into multiple postgraduate medical training programs, including cardiology, cardiac surgery, critical/intensive care medicine, emergency medicine and anaesthesiology. The numbers of postgraduate medical trainees in these programs at Queen’s University in August 2011 are 7, 0, 5, 28 and 25, respectively, making up about 14% of the total number of postgraduate medical trainees (468) at this institution [14].

Guidelines for physician training in echocardiography have been described by the American Society of Echocardiography (ASE) [15] and can be categorized into three consecutive levels of competence: Levels 1-3, respectively. It is recommended by ASE that all cardiologists obtain at least the most basic level of training. At this introductory level, the trainee needs to obtain thorough understanding of the principles, applications and instrumentation of echocardiography as well as its limitations. The trainee should also gain a thorough understanding of functional anatomy and physiology of the heart and great vessels as well as its hemodynamic properties as they relate to echocardiography. Lastly, the trainee should be able to recognize common pathologies and to correlate echocardiographic findings to discoveries from other diagnostic techniques. Clinical training at this level consists of interpreting 150 complete echocardiographic examinations (M mode, 2D and Doppler) and personally performing 75 of these studies. The subsequent two levels of training, levels 2 and 3, are primarily clinical and consist of interpreting a minimum of 300 studies and performing 150 of them, and interpreting a minimum of 750 and performing 300 of them, respectively.[15]

Non-cardiology medical trainees perform limited and goal-oriented echocardiographic examination. As a consequence of their limited use, they receive focused training in echocardiography that is tailored to their needs. As part of their training, non-cardiologists should still learn about ultrasound basics, standard views in transthoracic echocardiography, cardiac anatomy and the use of echocardiography to assess heart function.[16]

1.3. Ultrasound in undergraduate medical education

Researchers have investigated the feasibility of integrating ultrasound in undergraduate medical education since 1995 [5]. Echocardiography has been studied either as part of general ultrasound training or separately. Cardiac ultrasound has been introduced to medical students in multiple ways ranging from workshops that take several hours [12, 17, 18] to curricular

integration spanning several years [8]. Within the undergraduate medical curriculum, echocardiography has been incorporated into pre-existing courses in the core curriculum [5, 9], introduced as a topic within an independent year-long ultrasound course [19], or presented as part of an integrated ultrasound curriculum throughout all years of undergraduate medical education [8]. In addition, there have been interest groups developed to allow extracurricular exposure of medical students to US through student-run organizations where integration into the core curriculum was not feasible [13].

It has been shown that undergraduate medical students can gain adequate understanding of the principles, use and application of echocardiography as well as be able to perform a basic US exam of the heart with acceptable quality and within a reasonable time. Medical students at different levels of education were able to identify anatomical structures and interpret cardiac US images [8, 9, 12, 17]. In addition, students have been reported to gain necessary skills and technical knowledge to acquire at least fair quality cardiac ultrasound images, where adequate information is displayed to make an accurate diagnosis [8, 9, 12, 17, 18].

In addition, the benefits of studying ultrasound, including echocardiography, in preclinical medical years has been shown to enhance student learning about anatomy [8, 9, 17, 18], physiology [5, 8] and pathology [8]. It has been found to enhance knowledge of 3D anatomy and blood flow [9], visceral and surface anatomy as well as functional clinical (or “living”) anatomy [18]. Moreover, following participation in a pilot 5-hour ultrasound course, including cardiac, there was self-reported improvement in radiological anatomy [17]. Furthermore, echocardiography has been found to provide a good correlation between anatomy and physiology when incorporated into the practical component of a medical physiology course [5]. The students rated echocardiography as the most interesting and significant part of their physiology practical experience [5]. The researchers speculated that the reason for this was that echocardiography allowed the students to correlate the theoretical anatomical knowledge with the

practical physiological experience [5].

In addition, due to the possibility to repetitive scanning and the short time it takes to examine the heart Brunner and colleagues believe that incorporation of this technique to the physiology course can provide an alternate to animal models in the lab [5]. It may also prove more useful due to the possibility of using human models which is more relevant to the overall curriculum and clinical practice as well as allowing the observation of change in physiological processes in different conditions in the live human (e.g. rest vs. exercise).

Apart from enhancing knowledge on the basic medical sciences, ultrasound, including cardiac, has been found to develop clinical reasoning abilities [9, 12, 17, 18] and enhance the development of physical examination skills [7, 20, 21] in medical students.

The study and application of knowledge about ultrasound requires an integration of multiple disciplines such as physics, anatomy, physiology and clinical sciences which conveys application of the basic sciences to clinical practice [8]. This integrative way of thinking, where knowledge is rearranged to retrieve information from different disciplines, is considered a valuable skill as it prepares the student to deal with complex medical situations [5].

Due to the numerous advantages of learning ultrasound in the undergraduate medical years, it is recognized that ultrasound integration into the medical curriculum will greatly enhance medical education of the students [8]. Therefore, it is the ultimate goal of the School of Medicine in Queen's University to integrate US into the undergraduate medical curriculum. However, based on lessons learnt from previous other institutions that have taken this path it is clear that this has to be done gradually to avoid using large portions of time from the curriculum [8] and to avoid resistance from administrators at the school [13].

1.4. Online learning

The advantages of an online resource over other learning methods include accessibility,

availability, interactivity and ease of navigation, ease of content update and distribution, inclusion of multiple learning modalities and learner-driven learning pace and time [22-24]. The content and tools provided in the online resource should complement learning preferences of the students and be able to engage them [23]. Upon an online search for echocardiography-related online resources using different combinations of the terms “echocardiography”, “online module”, “atlas”, “learning tool”, “online resource”, “ultrasound of the heart”, “cardiac ultrasound” and “learning resource”, thirty resources were found. Detailed information about six of these resources are provided in Appendix A. The remaining resources either had restricted access or they displayed an error message and thus could not be evaluated. It was determined that, for a first-time learner, the self-directed online learning resource should provide sufficient information about the basics of echocardiography in text and visual form, following a logical progression. In addition, the multimedia files provided should be sufficiently labelled and of high-quality to enhance student learning. Lastly, the resource should provide motivate and engage the students using interactive tools and an easy-to-navigate layout. Of the six resources found there was not a single resource that encompassed all of the above-mentioned qualities. For example, the resource that seemed most targeted at first-time learners was the Yale Atlas of Echocardiography. However, this was an atlas rather than a module, providing a library of videos and images and virtually no text information.

1.5. Objectives and hypotheses

The purpose of this project was to create an online learning resource on echocardiography that is targeted to first-time (naïve) learners. The aim was to make this module available to all students and faculty associated with the School of Medicine at Queen’s University. It was hypothesized that this module will enhance learning by the undergraduate students about the anatomy and function of the cardiovascular system. Also, it was hypothesized that this module will help provide

a concise overview of introductory level training in echocardiography to postgraduate medical trainees.

1.6. Background information

1.6.1. Echocardiography theory

Echocardiography is an imaging technique that uses ultrasound waves to produce tomographic images (slices) of cardiac structures and to reflect blood flow. The ultrasound transducer (or probe) produces and transmits the ultrasound (US) waves into the patient's body. When the ultrasound waves exit the transducer they diverge to form an ultrasound beam that has the shape of a hand fan, with the narrow-most portion being closest to the transducer. Ultrasound waves are sound waves at high frequencies (>20 kHz). The transmission of US waves through a tissue depends on the acoustic impedance of that tissue. Acoustic impedance is a property of the tissue that relates to its resistance to the flow of US through it. When US waves hit an interface between tissues with different acoustic impedances it results in variable reflection of the ultrasound waves (echo) at the interface. It is this reflection of US that gets detected by the transducer and analyzed to produce different types of echocardiographic images. The greater the return of ultrasound from an interface the brighter the area appears on an echocardiographic image (or echocardiogram). [25]

1.6.2. Echocardiographic examination

An echocardiographic exam is often performed by a trained physician or a cardiac sonographer (under the supervision of a physician) and may take anywhere from a few minutes to an hour, depending on the clinical situation. There are two main routes for echocardiographic examination: trans-thoracic (TTE) or trans-esophageal (TEE), i.e. going through the thoracic wall

or the esophageal wall, respectively. Trans-esophageal echocardiography yields better quality images due to the shorter distance that the US beam has to travel to reach cardiac structures [25]. However, because it involves the insertion of an endoscopic device it is often less accessible than TTE. Therefore, TTE is often used due to its relative ease of use and accuracy. Both routes can produce a variety of echocardiographic modes, including M-mode, two-dimensional (2D), three-dimensional (3D), contrast and Doppler echocardiography [25]. Anatomic 2D images and physiologic Doppler data are often used during echocardiographic interpretation to assess heart anatomy and function.

1.6.3. Patient position

During a TTE exam the major concerns for image acquisition are the air-filled lungs and the bony thoracic cage because they interfere with the ultrasound beam. Therefore, the patient needs to be positioned in a certain way as to limit the interference by these structures with the US beam. The optimal patient position for a TTE exam is the left lateral decubitus position as it brings the heart close to the chest wall providing a shorter distance for the US beam to travel through. However, the patient may sometimes be asked to take a supine position if a decubitus orientation is not feasible (e.g. pregnant woman). Structures may move in and out of focus of the image in 2D due to respiratory motion and cardiac contraction. Therefore, where applicable, the patient may be asked to hold breath to avoid "respiratory motion artefact". Once the patient assumes position the electrocardiographic electrodes are attached to the patient's chest and a water-soluble gel is applied to where the transducer is to be placed. This is an important step because the gel provides a continuous interface between the transducer and the chest wall. When placing the transducer onto the chest wall, the examiner often looks for points as to avoid the bony thoracic cage (e.g. intercostal space). This helps provide optimal access of ultrasound to the heart and back. [25]

1.6.4. Transducer placement and position

The location of the transducer on the chest wall is more commonly referred to as an 'acoustic window' in TTE [25] and it is determined by the location and orientation of the heart within the thorax. The morphology of the heart resembles a pyramid that has fallen on its side such that its apex (narrow-most portion) points inferiorly to the left side of the body and the base faces posteriorly [26] [Figure 1 (a)]. The remaining four surfaces of the heart are the anterior (or costal), left pulmonary, right pulmonary and inferior (or diaphragmatic). These surfaces face the anterior thoracic wall, the left lung, the right lung and the thoracic diaphragm, respectively. Certain anatomical landmarks on the anterior thoracic wall can be used to locate the heart within the thorax. Anteriorly, the four corners of the heart can be roughly located from superior right, in a counter-clockwise direction, at the levels of costal cartilage of third right rib, costal cartilage of sixth right rib, fifth left intercostal space and second left intercostal space, respectively [26] [Figure 1 (b)]. Based on these anatomical landmarks on the anterior thoracic wall there are four acoustic windows in TTE [Figure 2]:

1. Parasternal (PS): in the left third or fourth intercostal space, adjacent to sternum
2. Apical: in the left fifth intercostal space at the level of the apex of the heart
3. Subcostal: at the apex of the infra-sternal/subcostal angle
4. Suprasternal: in the suprasternal notch [25]

Within a given window the transducer can be manipulated in its position to give different acoustic planes. The plane of an echocardiographic image is described as the axis of the heart through which the ultrasound beam passes. The transducer can be tilted (rocking the tip of the transducer to allow the imaging of different areas within the same plane), angled (moving the tip of the transducer so that it can produce different planes that are parallel to the original plane) or rotated (to give planes that intersect the original plane) to change the plane within a given window [25]. There are four main standard acoustic planes in echocardiography [Figure 3]:

- Long-axis (LAX): Along the long axis of the left ventricle cutting through the apex of the heart up through the centre of the ascending aorta bisecting the mitral valve and the aortic valve on the way [Figure 3 (a)].
- Short-axis (SAX): Along an axis that is perpendicular to the LAX plane producing a cross-sectional view of the heart [Figure 3 (b)].
- Four-chamber (4C): Perpendicular to the SAX plane and 60° to the LAX plane resulting in an image where all four chambers of the heart and the two atrio-ventricular valves (mitral and tricuspid) are visible [Figure 3 (c)].
- Two-chamber (2C): Rotated so that it traverses an axis that is midway between LAX and 4C planes resulting in an image of the left atrium, left ventricle and the mitral valve in between [Figure 3 (d)]. [25]

1.6.5. Image orientation

Most echocardiography labs follow the guidelines put together by the American Society of Echocardiography (ASE) for adult echocardiographic image orientation. The ASE recommends that the image is oriented such that the top-most part of the image is the part of the heart that is closest to the transducer on the patient (narrow portion of the cone-shaped image). In addition, in short-axis the right side of the heart is shown on the left-hand side as if looking at the heart from the apex up onto the base. Likewise, in the four-chamber views the right side of the heart is shown on the left-hand side of the image as if looking at the heart from below, similar to computed tomography (CT) images. Lastly, in long-axis the basal structures appear on the right-hand side of the image as if looking at the heart from the left side of the body towards the right side. [25]

1.6.6. Standard tomographic views

Each individual tomographic image in echocardiography is characterized by an acoustic window (transducer position) and an acoustic plane (axis of the heart through which the US beam passes). There are thirteen tomographic views that are commonly used in a standard echocardiographic exam [25] [Figures 4-16] and they are described below:

Parasternal long-axis (PS LAX)

The transducer is placed in the parasternal window and its head angled laterally [Figure 4 (a)]. This yields a view of the left ventricular inflow and outflow tracts; the mitral valve can be seen between the atrium and ventricle, and the aorta is seen as it extends out from the left ventricle anteriorly [Figures 4 (b) and (c)].

Parasternal right ventricular inflow tract (PS RVIT)

From the PS LAX view, the transducer can be moved more apically and tilted medially to yield a view of the right ventricular outflow tract [Figure 5 (a)]. In this view part of the right atrium is seen as it empties into the right ventricle through the tricuspid valve [Figure 5 (b)]. This view is important for the assessment of the tricuspid valve and right ventricular functions [25].

Parasternal short-axis (PS SAX) at the levels of aortic valve, mitral valve, mid-ventricle and apex

From the PS LAX view, the transducer can be rotated 90° in the clockwise direction to obtain a view of the heart in its short-axis. In this orientation the transducer can be tilted superiorly or inferiorly to give short-axis views at different levels of the heart. The most commonly used short-axis views in echocardiography, from basal to apical, are at the levels of aortic valve, mitral valve, papillary muscle of the left ventricle (mid-ventricle) and apex, respectively [Figures 6-9].

The plane through which the US beam passes in PS SAX view at the level of the aortic valve is shown in figure 6 (a). At the level of the aortic valve, the aorta can be seen in cross-section with the three cusps of the aortic valve, right, left and non-coronary cusps [Figures 6 (b) and (c)]. The right ventricular inflow and outflow tracts can be seen surrounding the aorta like a crescent. The right atrium can be seen to the left-hand side of the image emptying into the right ventricle through the tricuspid valve, and the right ventricle emptying into the pulmonary trunk through the pulmonic valve [Figures 6 (b) and (c)].

The plane through which the US beam passes in PS SAX view at the level of the mitral valve is shown in figure 7 (a). At this level, both leaflets of the mitral valve can be seen anteriorly and posteriorly, respectively. The tricuspid valve is more superior to the mitral valve and thus cannot be seen in this view. Figures 7 (b) and (c) demonstrate the structures observed in this view on a sectioned gross heart and on an echocardiographic image, respectively.

The plane through which the US beam passes in PS SAX view at the level of the mid-ventricle is shown in figure 8 (a). At this level the ventricles can be seen in cross section; the left ventricle looks round and the right ventricle forms a crescent shape around the right side of the left ventricle (left-hand side of echocardiogram in figure 8 (b)). The anterior and posterior papillary muscles of the left ventricle can also be seen. Figures 8 (b) and (c) demonstrate the structures observed in this view on a sectioned heart and on an echocardiographic image, respectively.

The plane through which the US beam passes in PS SAX view at the level of the apex is shown in figure 9 (a). At the apical level the apical portions of the two ventricles are observed. Figures 9 (b) and (c) demonstrate the structures observed in this view on a sectioned gross heart and on an echocardiographic image, respectively.

Apical four-chamber (Apical 4C)

The transducer can be placed in the apical window and oriented so that it is perpendicular to both SAX and LAX planes to obtain the apical 4C view [Figure 10 (a)]. This location and orientation of the transducer yields a view of the four chambers of the heart and the two atrio-ventricular valves (tricuspid and mitral). Figures 10 (b) and (c) demonstrate the structures observed in this view on a sectioned gross heart and on an echocardiographic image, respectively.

Apical five-chamber (Apical 5C)

From the apical 4C view the transducer can be slightly rotated in the clockwise direction to bring up the aortic valve in cross-section [Figure 11 (a)]. The proximal aorta in cross-section is considered the “fifth chamber” in this view. Figures 11 (b) and (c) demonstrate the structures observed in this view on a sectioned gross heart and on an echocardiographic image, respectively.

Apical two-chamber (Apical 2C)

From the apical 4C view the apical 2C view can be obtained by rotating the transducer 60° in the counter-clockwise direction [Figure 12 (a)]. This orientation of the transducer yields a view where the left atrium and ventricle are seen in long axis with the mitral valve in between. This view is often used to examine the anterior and posterior/infero-lateral walls of the left ventricle (on the right and left sides of the echocardiogram, respectively). Figures 12 (b) and (c) demonstrate the structures observed in this view on a sectioned gross heart and on an echocardiographic image, respectively.

Apical three-chamber/long-axis (Apical 3C/LAX)

From the apical 2C view, the transducer can be rotated 60° in the counter clockwise direction (total of 120° from apical 4C) to yield a view similar to PS LAX [Figure 13 (a)]. This is

called the apical LAX or apical 3C view, where the aorta is considered as the “third chamber” in this view. Figures 13 (b) and (c) demonstrate the structures observed in this view on a sectioned gross heart and on an echocardiographic image, respectively.

Subcostal views [four-chamber (subcostal 4C) and short-axis (subcostal SAX)]

In the subcostal window the transducer is placed on the apex of the subcostal angle overlying the xyphoid process of the sternum. The head of transducer is tilted upwards to give subcostal views of the heart. From this location, the first structure that the US beam encounters after the abdominal wall is the liver, which appears at the top of all subcostal images. There are two common views from this window and these consist of the four-chamber and short-axis, depending on the angle and rotation of the transducer.

The plane through which the US beam passes in subcostal 4C view is shown in figure 14 (a). Structures observed in the 4C view include the free wall of the right ventricle, the midsection of inter-ventricular septum and the anterolateral left ventricular wall. The inter-atrial septum can be evaluated in this view because it is perpendicular to US beam. Figure 14 (b) demonstrates the structures observed in this view on an echocardiographic image.

The plane through which the US beam passes in subcostal SAX view is shown in figure 15 (a). The SAX view can be used when an evaluation using the parasternal window is not adequate. Figure 15 (b) demonstrates the structures observed in this view on an echocardiographic image.

Suprasternal long-axis of aortic arch (Suprasternal)

The transducer can be placed in the suprasternal notch and tilted downwards to get the aortic arch in long axis. Figure 16 demonstrates the structures observed in this view on an echocardiographic image.

In all cases other types of tomographic views may be used to allow a more complete examination of the heart. One view that is often used to evaluate the inferior vena cava is the subcostal inferior vena cava (subcostal IVC) view. The probe is placed in the apex of the subcostal angle and angled superiorly to view the inferior vena cava in long-axis as it enters the right atrium. In this view, the size of the IVC can be measured at 1-2cm from its entry point into right atrium. The proximal portion of the abdominal aorta can also be seen in long axis medial to the IVC. [25]

1.6.7. Assessment of heart function using echocardiography

Echocardiography can be used to assess heart structure and function using mainly two specific modes, namely 2D images and Doppler blood flow data. These modes are described below.

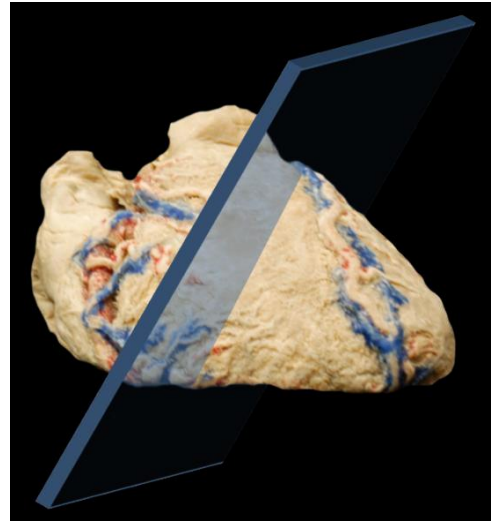
2D Echocardiography

Due to the shape and orientation of the heart different parts of the same structure may appear in various views. Therefore, it is best to assess the heart from all standard tomographic views. However, specific views may be more useful in the assessment of different structures. For example, different parts of the right ventricle can be seen in every standard tomographic view. Due to the orientation in which it wraps around the left ventricle, the right ventricle appears in an oblique section in every standard tomographic view. To obtain a comprehensive evaluation of the right ventricle the most useful views are PS LAX, PS RVIT, PS SAX (aortic valve), PS SAX (mid-ventricle) and apical 4C. [27]

Doppler echocardiography

Doppler ultrasound is based on the principle known as the Doppler Effect (also known as

Doppler shift). According to this concept, the frequency of the echo of a sound from an object moving towards the listener (receiver) is higher than that of the original sound transmitted by the source; similarly, the frequency of the echo of a sound reflected off an object moving away from the transducer is lower than that of the original sound transmitted by the source. Doppler echocardiography is based on this idea of the change in frequency of ultrasound as a result of its backscatter by the moving blood cells within the heart [25]. The speed and direction of blood flow can be determined using Doppler echocardiography to assess hemodynamic function [25].



(a)

(b)

(c)

(d)

Figure 3 Main standard acoustic planes in echocardiography: (a) *Long-axis* through the long-axis of the left ventricle; (b) *Short-axis* perpendicular to long-axis; (c) *Four-chamber* perpendicular to short-axis and 60° to long-axis; (d) *Two-chamber* midway between four-chamber and long-axis. The heart is oriented as it would appear anteriorly. The blue rectangle represents the ultrasound beam passing through an axis of the heart.

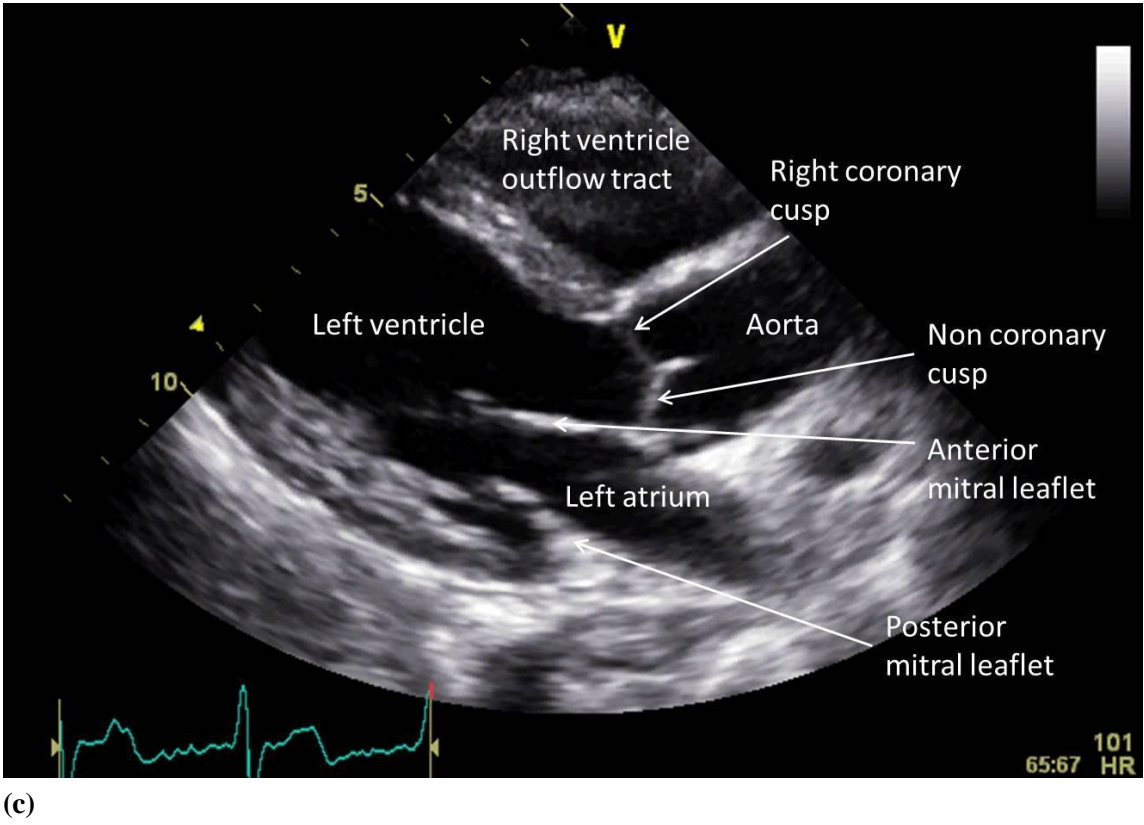
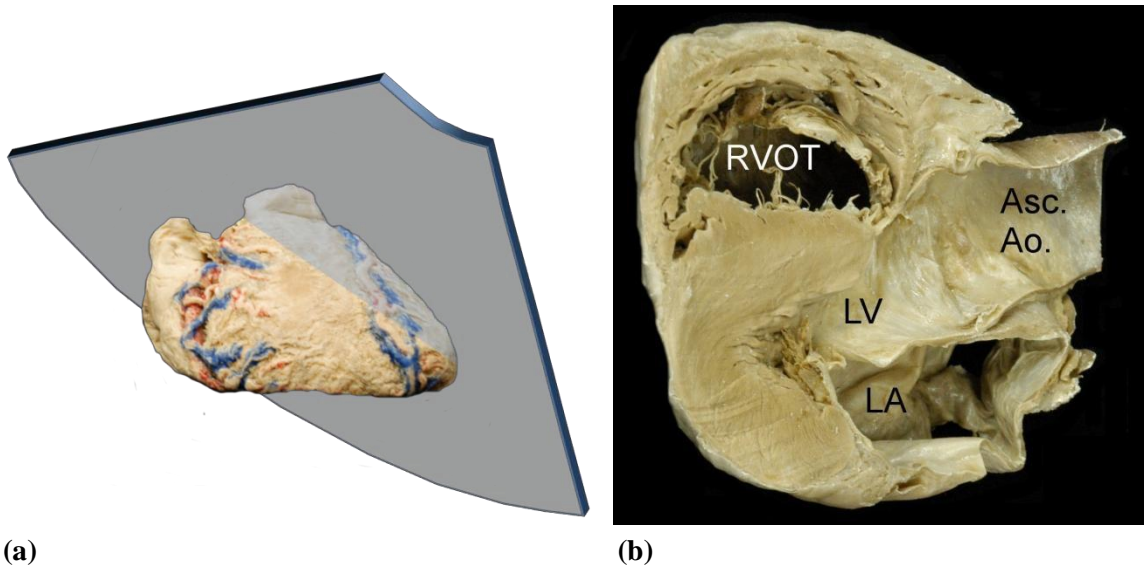
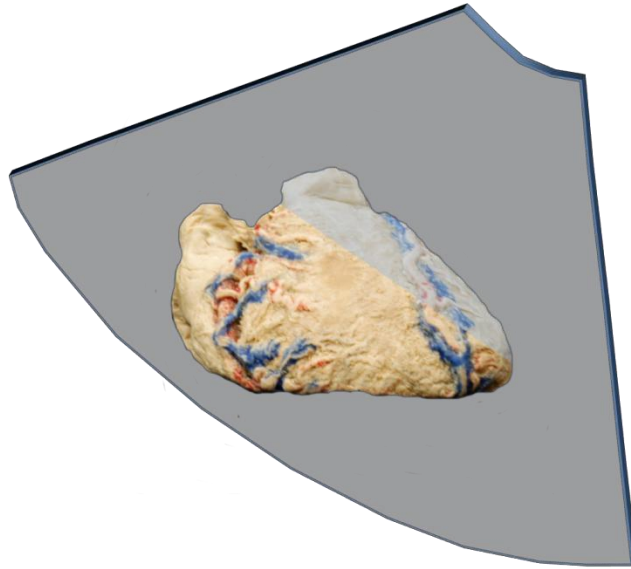
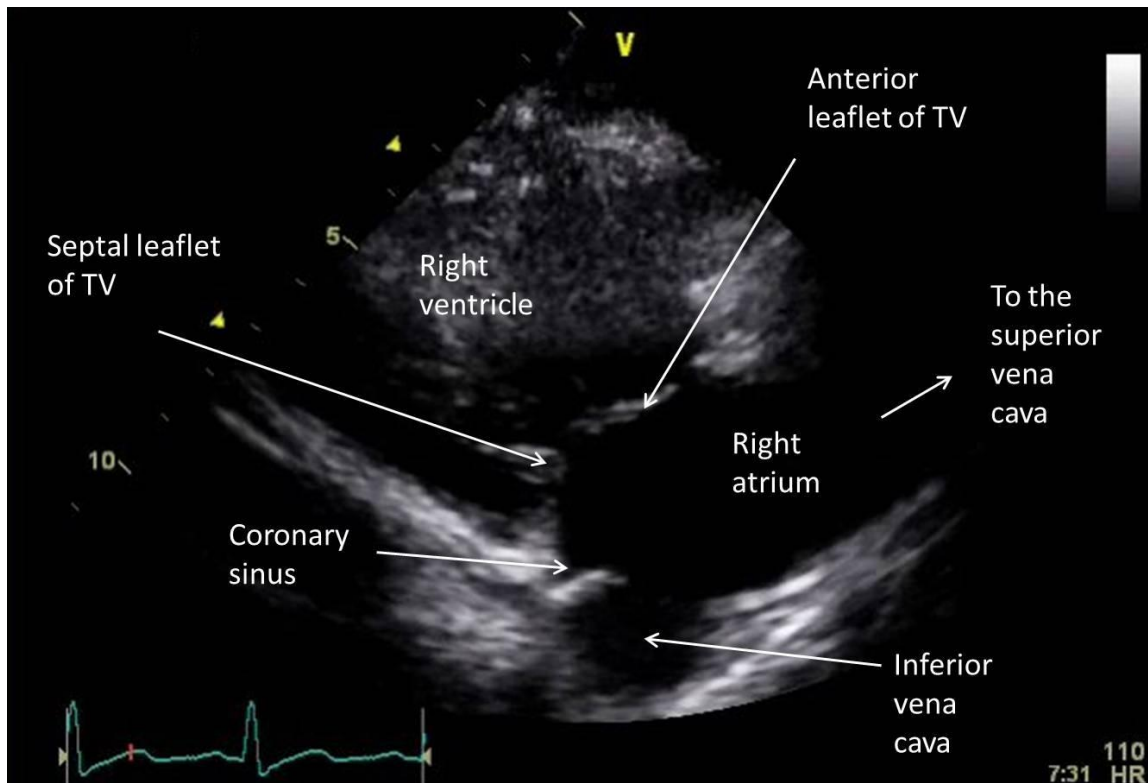


Figure 4 Parasternal long-axis view (PS LAX): (a) Plane through which beam passes in PS LAX (The blue fan represents the ultrasound beam passing through an axis of the heart); (b) Gross heart specimen sliced to represent the PS LAX view; (c) Still echocardiographic image of the heart in PS LAX. *LV* Left Ventricle; *LA* Left Atrium; *Asc. Ao.* Ascending Aorta; *RVOT* Right Ventricular Outflow Tract.



(a)



(b)

Figure 5 Parasternal right ventricular inflow tract view (PS RVIT): (a) Plane through which beam passes in PS RVIT (The blue fan represents the ultrasound beam passing through an axis of the heart); (b) Still echocardiographic image of the heart in PS RVIT. TV Tricuspid Valve.

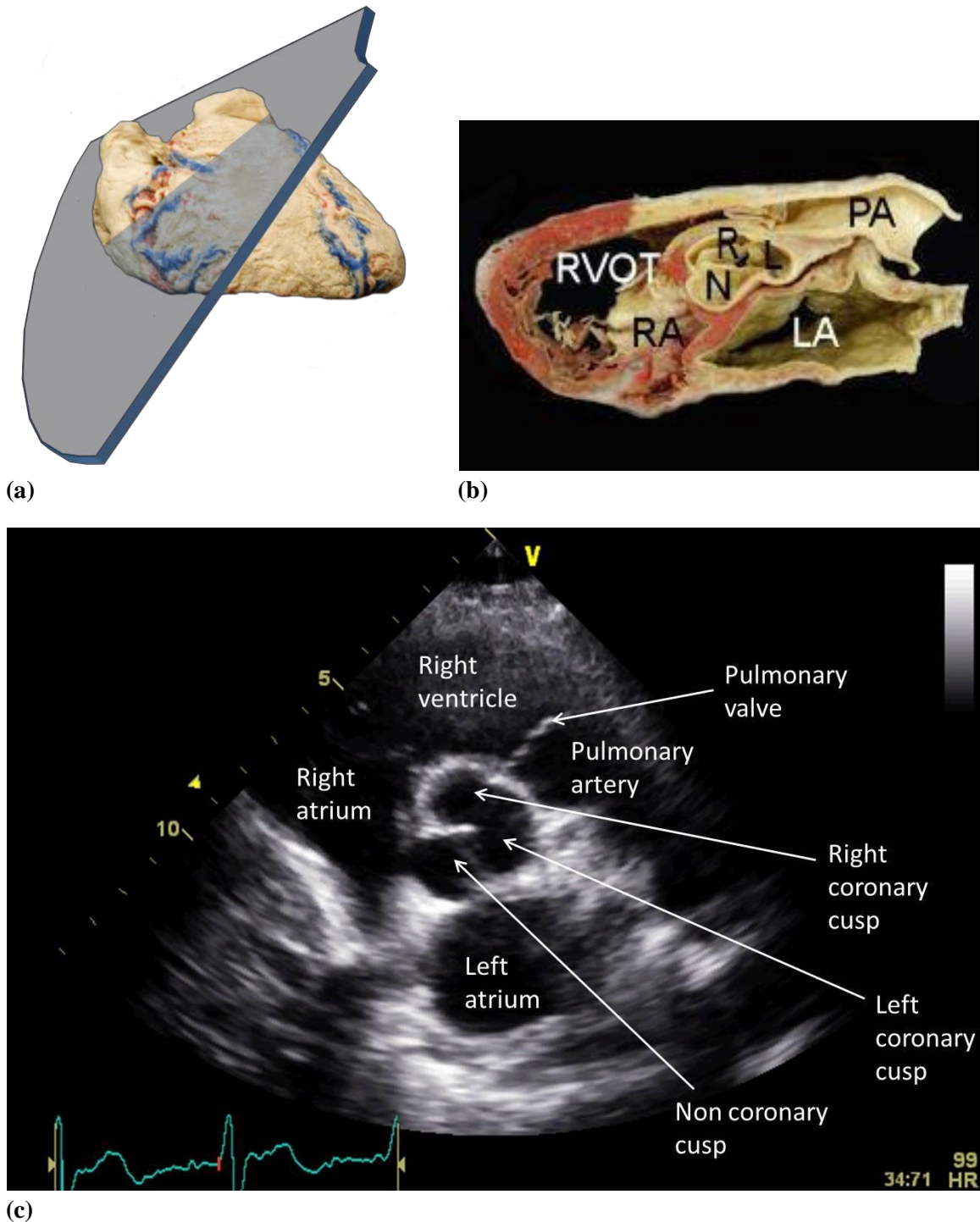


Figure 6 Parasternal short-axis view at the aortic valve (PS SAX Aortic valve): (a) Plane through which beam passes in PS SAX Aortic valve (The blue fan represents the ultrasound beam passing through an axis of the heart); (b) Gross heart specimen sliced to represent the PS SAX Aortic valve view; (c) Still echocardiographic image of the heart in PS SAX Aortic valve. LA Left Atrium; RA Right Atrium; RVOT Right Ventricular Outflow Tract; PA Pulmonary Artery; R Right Coronary Cusp of the Aortic Valve; L Left Coronary Cusp of the Aortic Valve; N Non Coronary Cusp of the Aortic Valve.

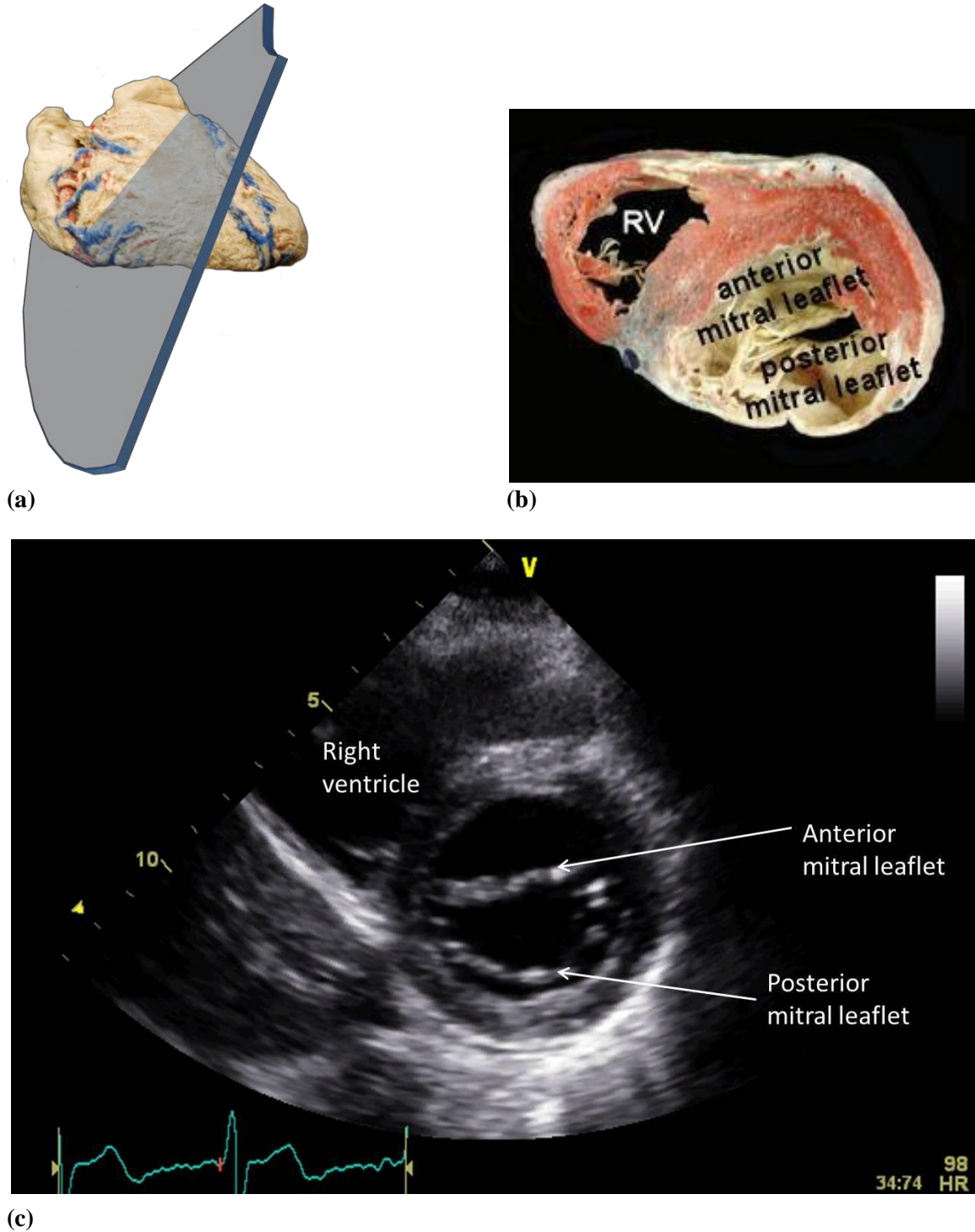


Figure 7 Parasternal short-axis view at the mitral valve (PS SAX Mitral): (a) Plane through which beam passes in PS SAX Mitral (The blue fan represents the ultrasound beam passing through an axis of the heart); (b) Gross heart specimen sliced to represent the PS SAX Mitral view; (c) Still echocardiographic image of the heart in PS SAX Mitral. *RV* Right Ventricle.

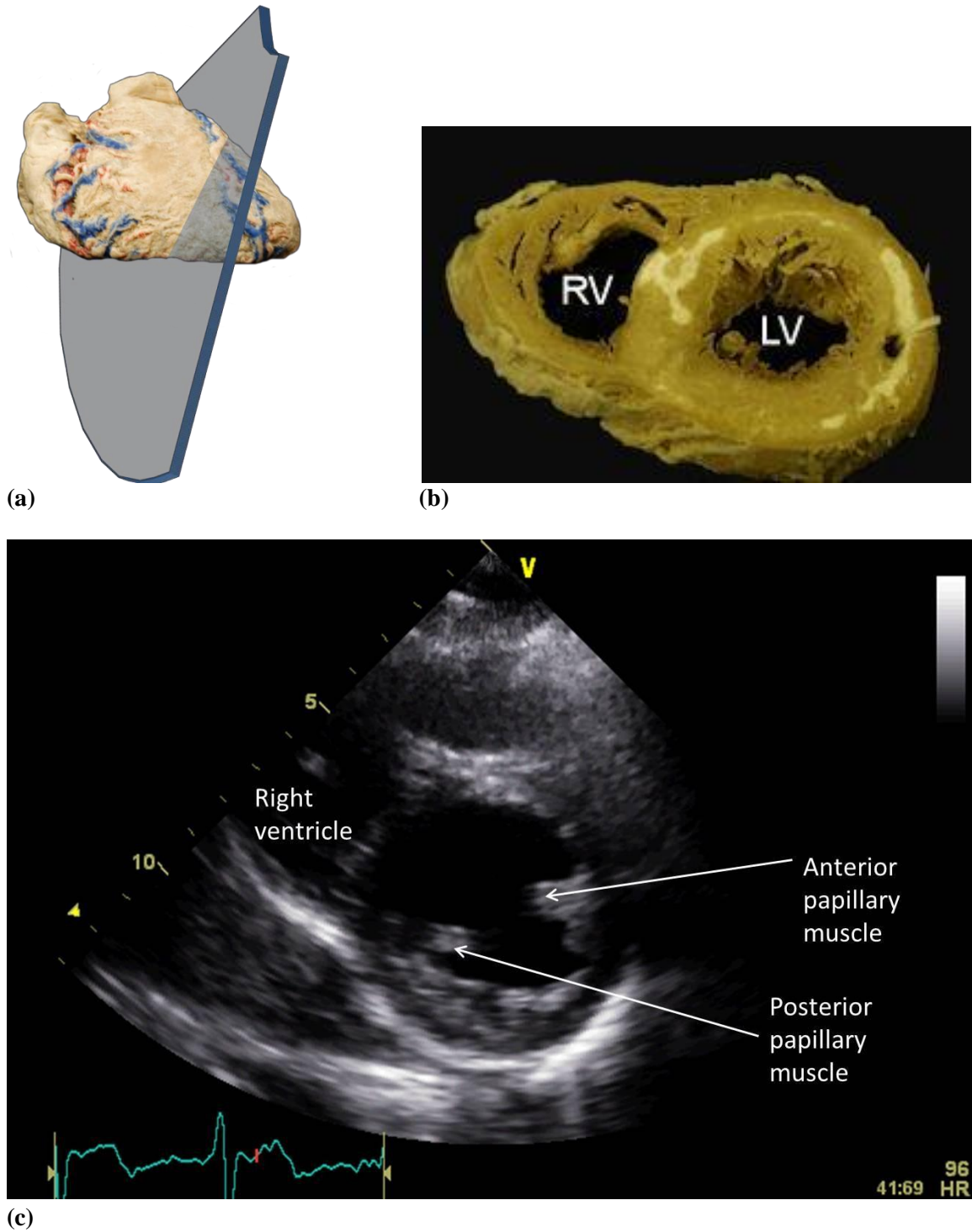


Figure 8 Parasternal short-axis view at the mid-ventricle (PS SAX Mid-ventricle): (a) Plane through which beam passes in PS SAX Mid-ventricle (The blue fan represents the ultrasound beam passing through an axis of the heart); (b) Gross heart specimen sliced to represent the PS SAX Mid-ventricle view; (c) Still echocardiographic image of the heart in PS SAX Mid-ventricle. *RV* Right Ventricle; *LV* Left Ventricle.

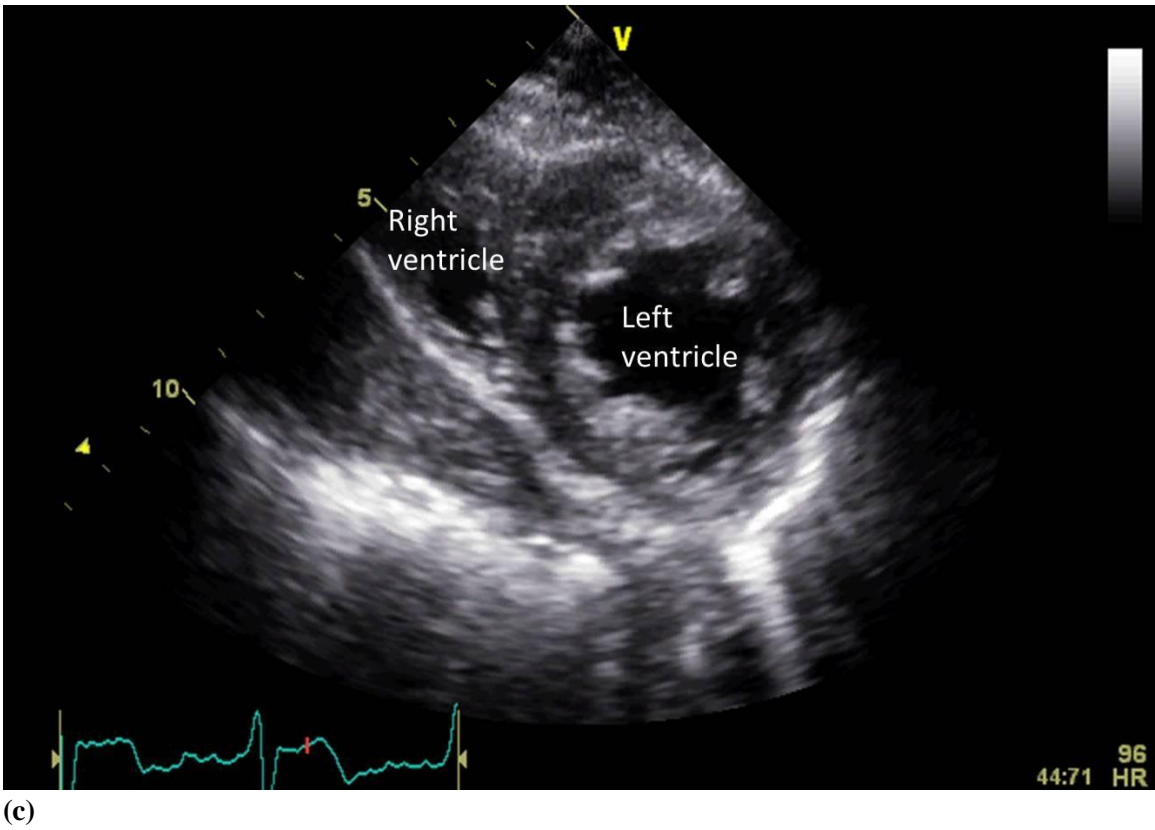
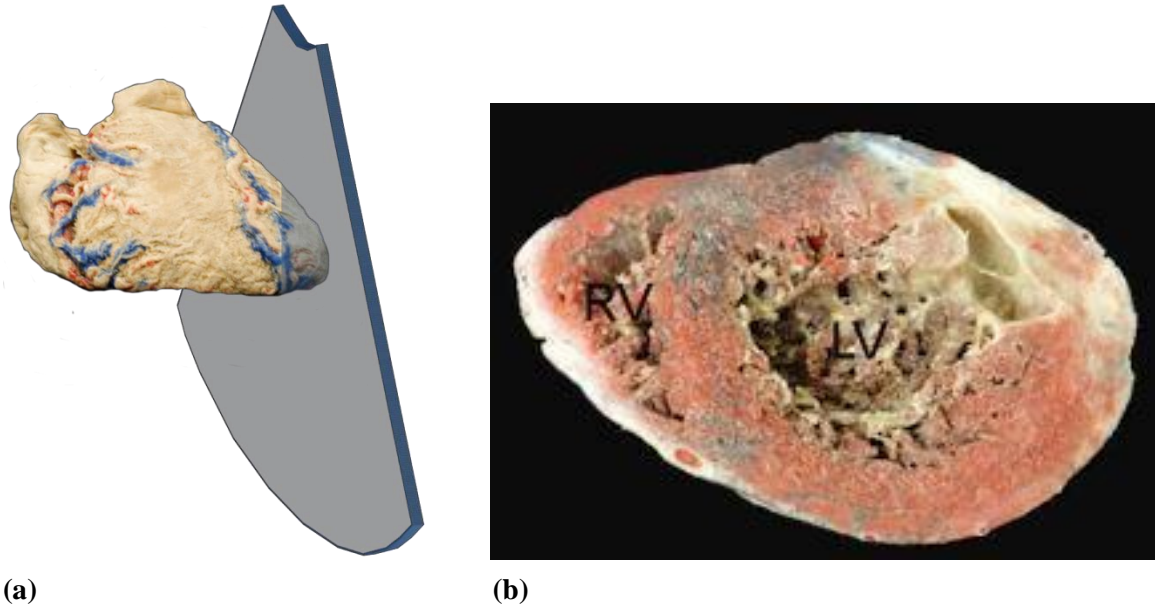


Figure 9 Parasternal short-axis view at the apex (PS SAX Apex): (a) Plane through which beam passes in PS SAX Apex (The blue fan represents the ultrasound beam passing through an axis of the heart); (b) Gross heart specimen sliced to represent the PS SAX Apex view; (c) Still echocardiographic image of the heart in PS SAX Apex. *RV* Right Ventricle; *LV* Left Ventricle.

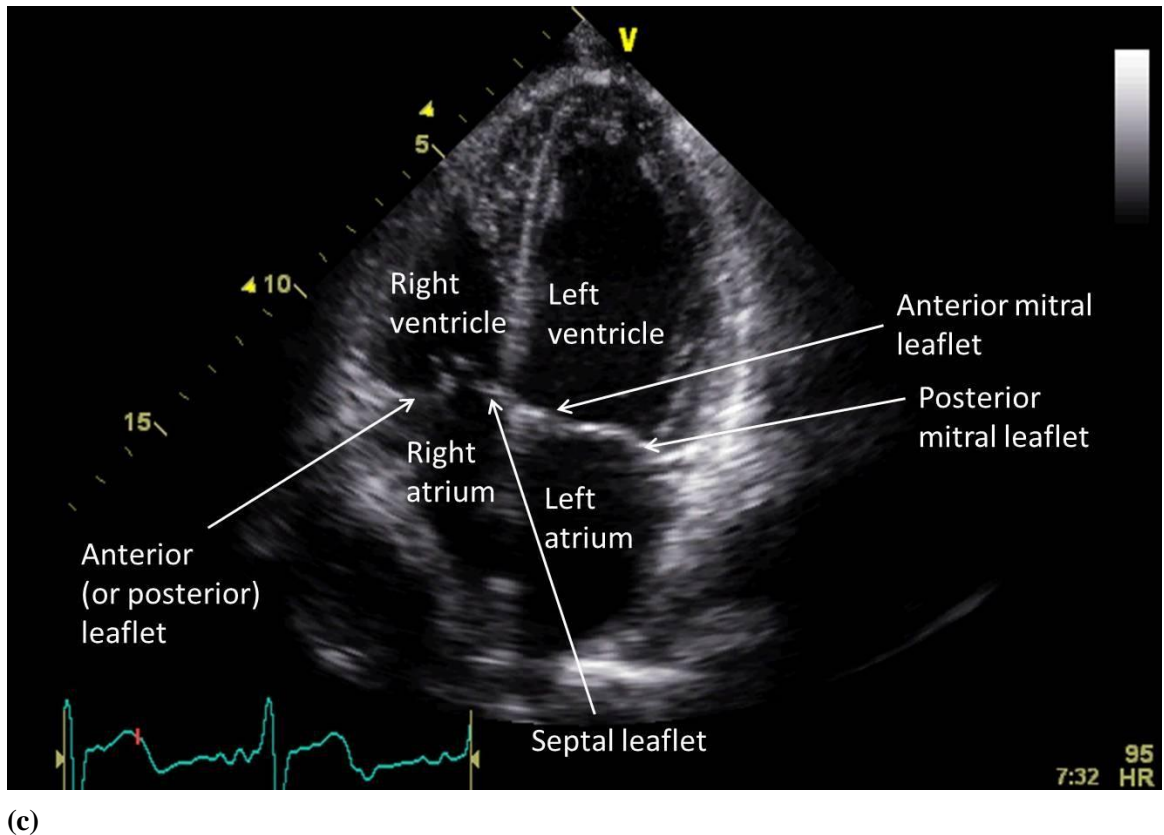
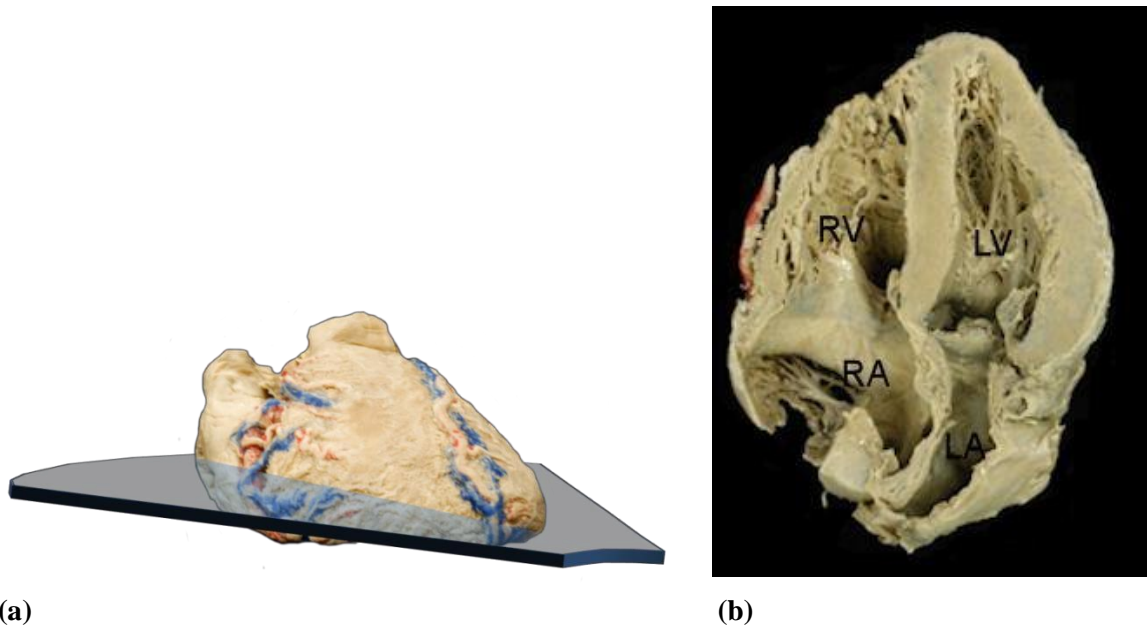


Figure 10 Apical four-chamber view (Apical 4C): (a) Plane through which beam passes in apical 4C (The blue fan represents the ultrasound beam passing through an axis of the heart); (b) Gross heart specimen sliced to represent the apical 4C view; (c) Still echocardiographic image of the heart in apical 4C. RA Right Atrium; RV Right Ventricle; LA Left Atrium; LV Left Ventricle.

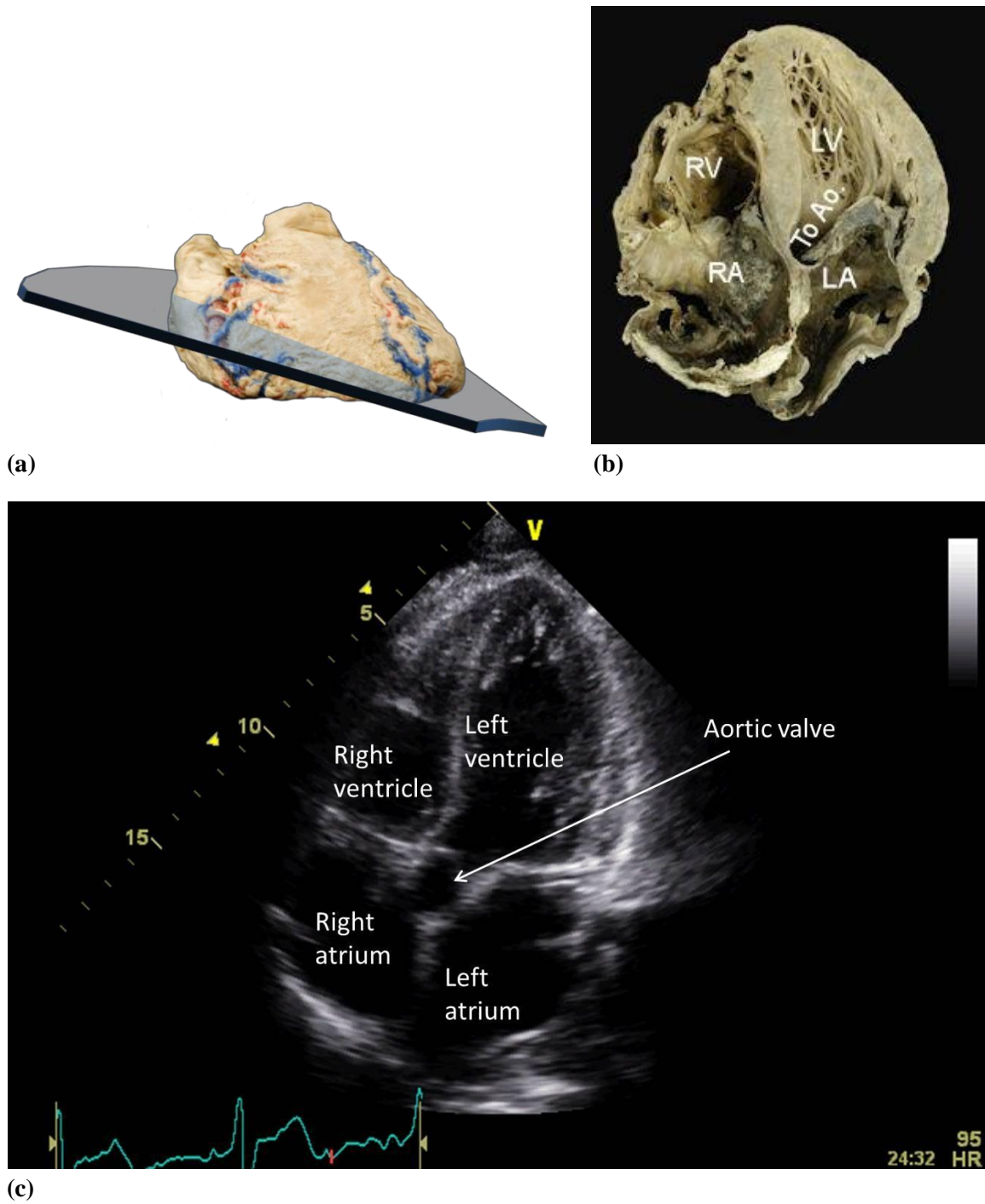


Figure 11 Apical five-chamber view (Apical 5C): (a) Plane through which beam passes in apical 5C (The blue fan represents the ultrasound beam passing through an axis of the heart); (b) Gross heart specimen sliced to represent the apical 5C view; (c) Still echocardiographic image of the heart in apical 5C. *RA* Right Atrium; *RV* Right Ventricle; *LA* Left Atrium; *LV* Left Ventricle; *To Ao.* To the Aorta.

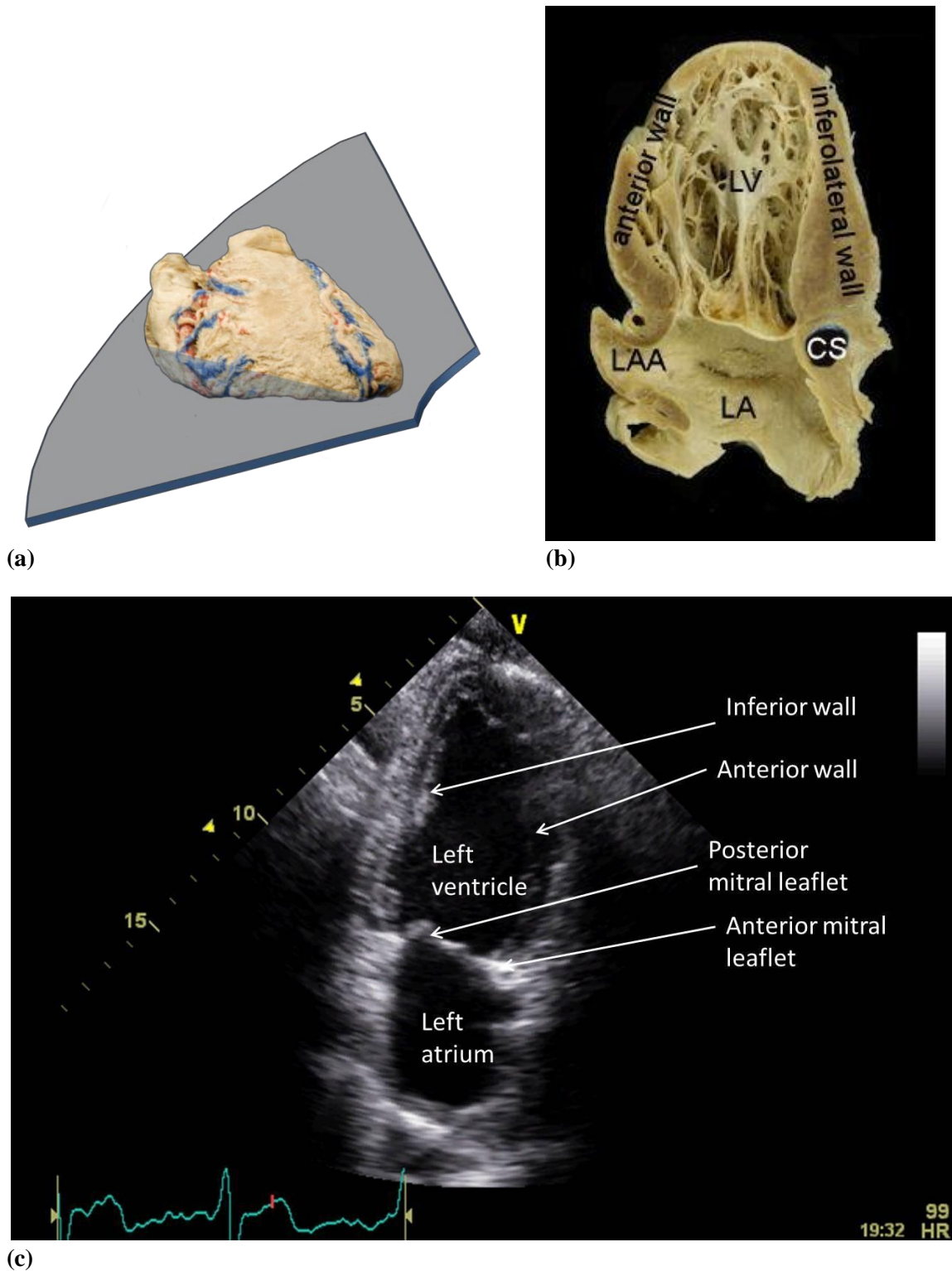
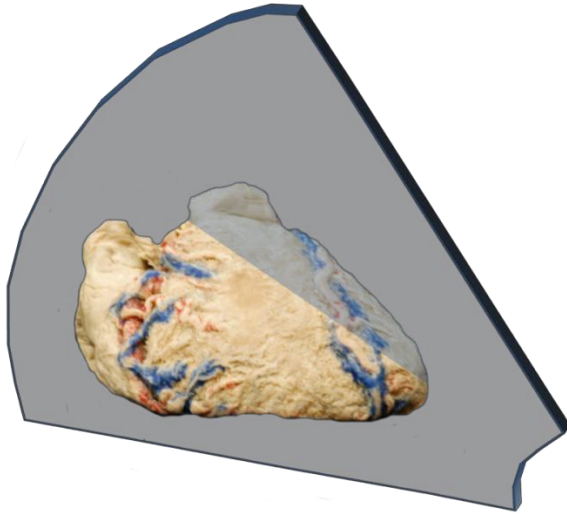
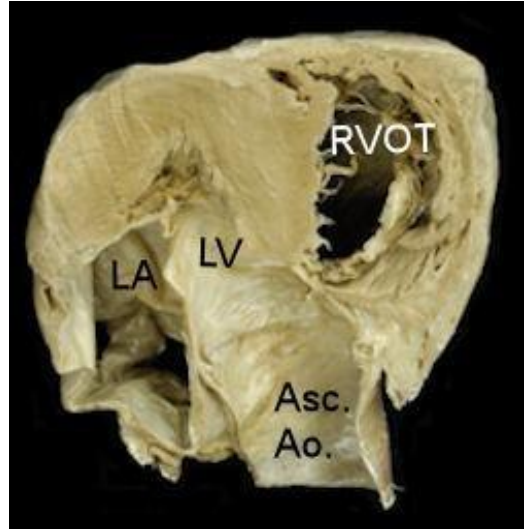


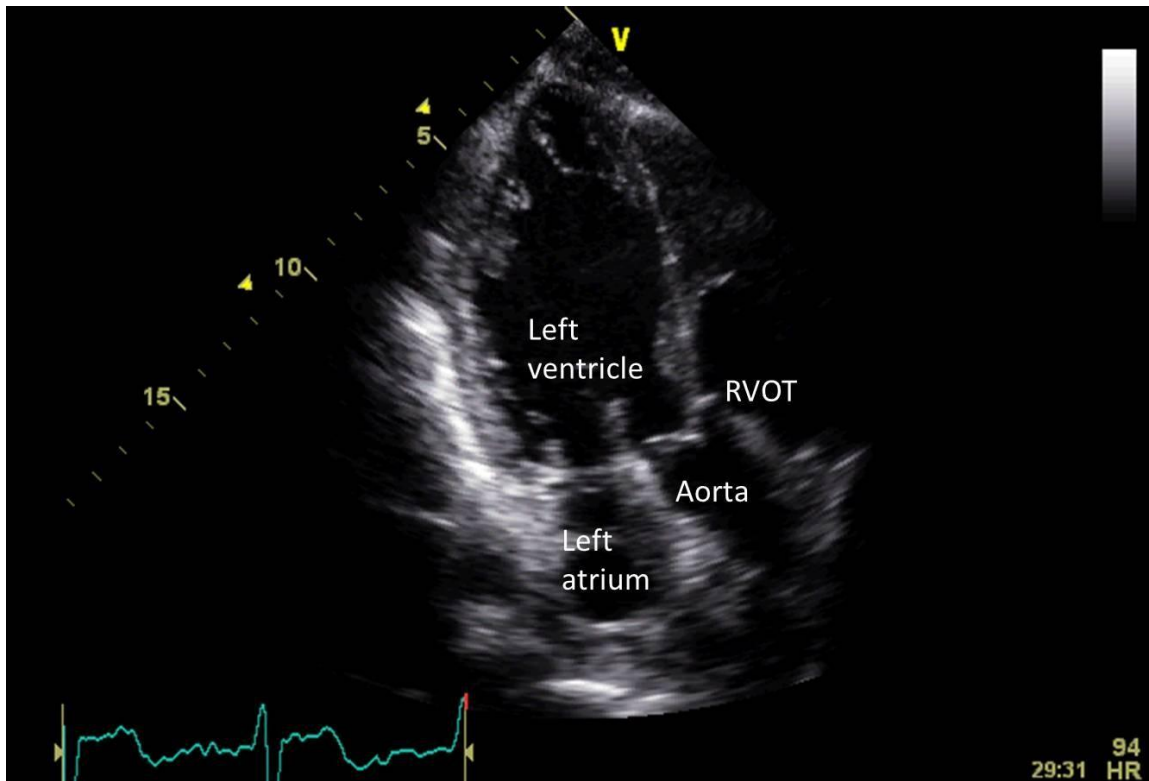
Figure 12 Apical two-chamber view (Apical 2C): (a) Plane through which beam passes in apical 2C (The blue fan represents the ultrasound beam passing through an axis of the heart); (b) Gross heart specimen sliced to represent the apical 2C view; (c) Still echocardiographic image of the heart in apical 2C. *LA* Left Atrium; *LAA* Left Atrial Appendage; *LV* Left Ventricle; *CS* Coronary Sinus.



(a)




(b)

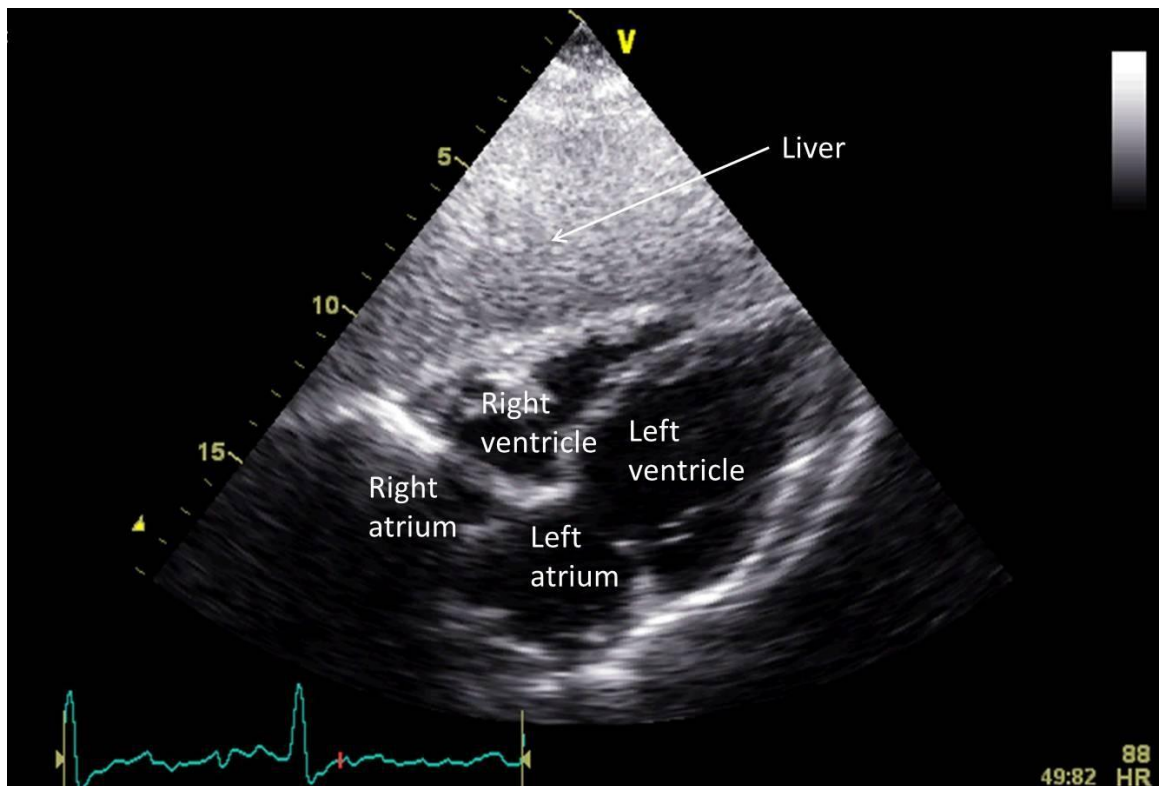


(c)

Figure 13 Apical three-chamber/long-axis view (Apical 3C/LAX): (a) Plane through which beam passes in apical 3C/LAX (The blue fan represents the ultrasound beam passing through an axis of the heart); (b) Gross heart specimen sliced to represent the apical 3C/LAX view; (c) Still echocardiographic image of the heart in apical 3C/LAX. LA Left Atrium; LV Left Ventricle; Asc. Ao. Ascending Aorta; RVOT Right Ventricular Outflow Tract.



(a)



(b)

Figure 14 Subcostal four-chamber view (Subcostal 4C): (a) Plane through which beam passes in subcostal 4C (The blue fan represents the ultrasound beam passing through an axis of the heart); (b) Still echocardiographic image of the heart in subcostal 4C.

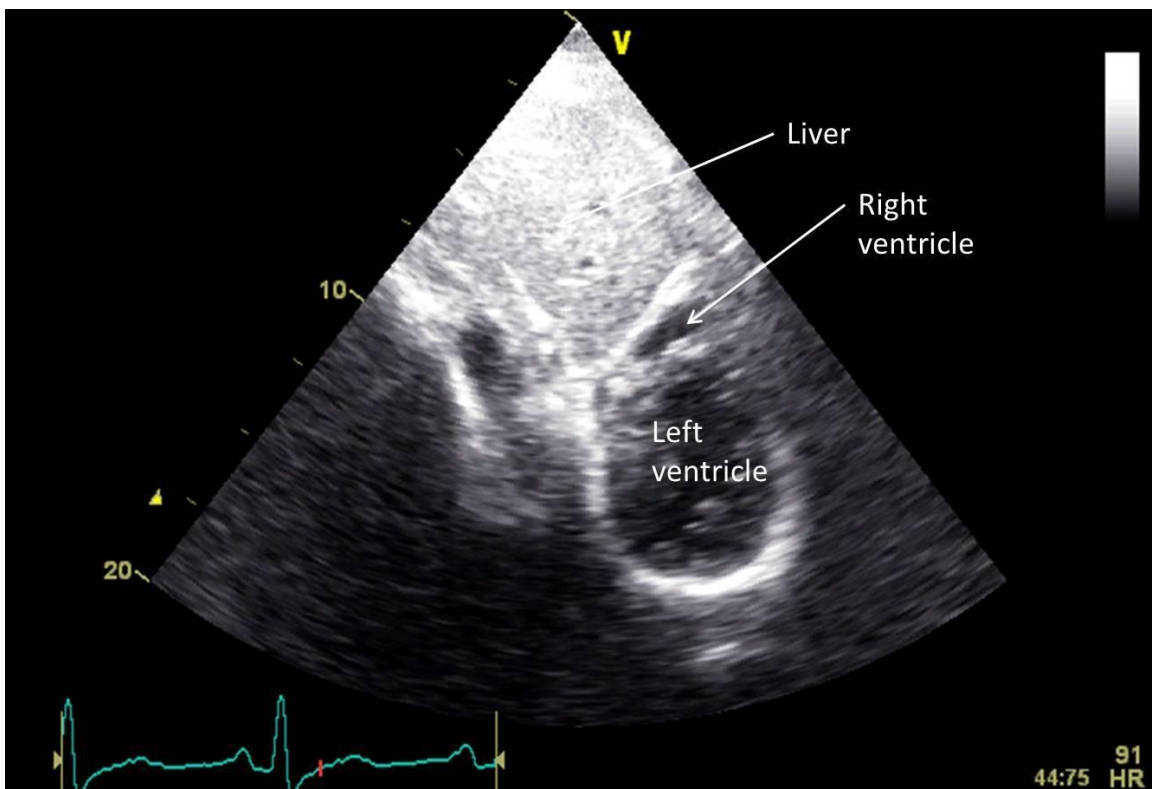
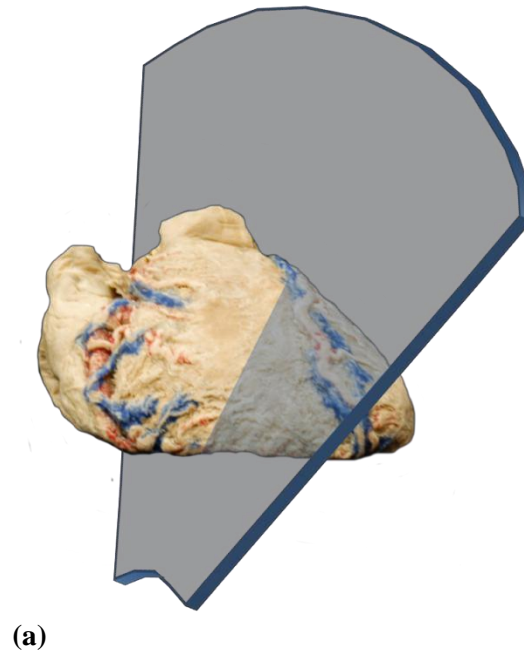


Figure 15 Subcostal short-axis view (Subcostal SAX): (a) Plane through which beam passes in subcostal SAX (The blue fan represents the ultrasound beam passing through an axis of the heart); (b) Still echocardiographic image of the heart in subcostal SAX.

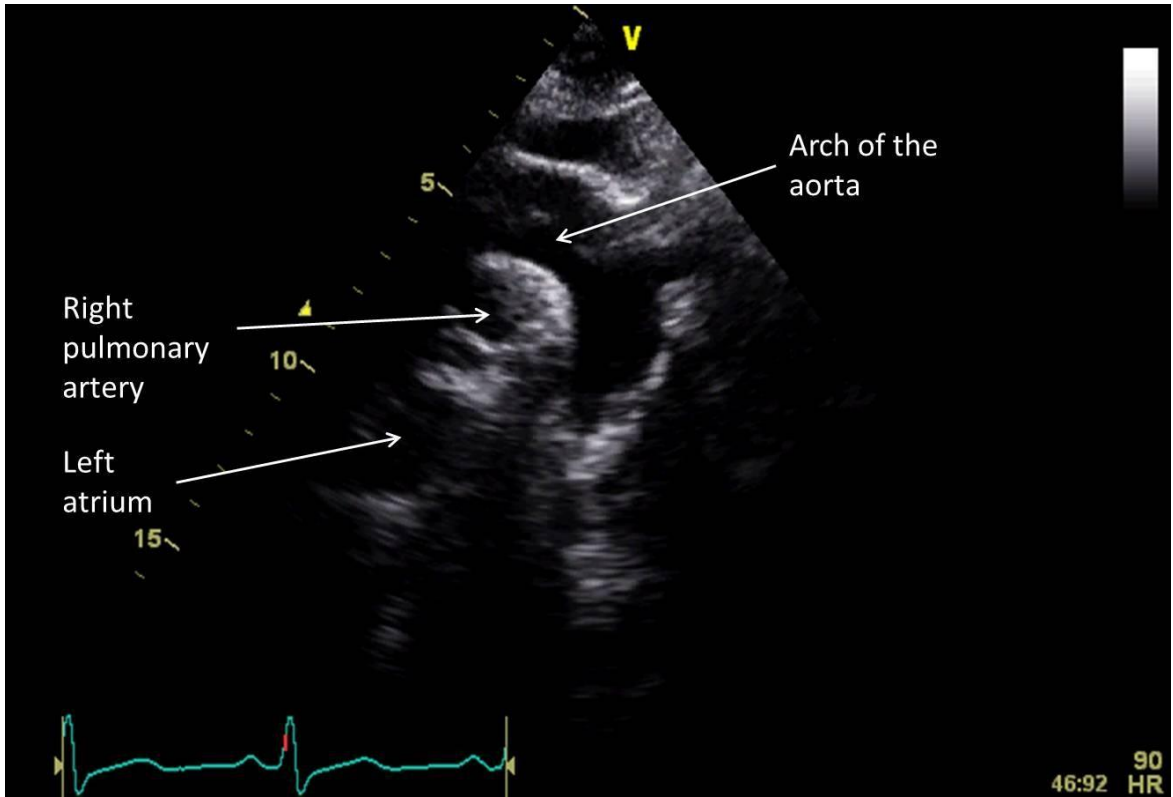


Figure 16 Echocardiographic image of the suprasternal long-axis of the aortic arch (Suprasternal).

CHAPTER 2

METHODS

Approval for this study was obtained from the Research Ethics Board at Queen's University. This project was made possible through the collaboration between the Division of Cardiology, Department of Biomedical and Molecular Sciences and the Medical Education Technologies Unit (MEdTech) at Queen's University. Prior to creating the module, content was carefully selected and put together using Otto's Textbook of Clinical Echocardiography [25] and Gray's Anatomy for Students [26]. Multimedia files included anatomical illustrations of heart anatomy and 3D representation of the heart, echocardiographic images and videos with their associated summary tables and images of plastinated heart slices. The images and videos were critically prepared and assessed using a preliminary survey. Based on the results of this preliminary survey the module was then developed.

2.1. Selection of content

The content of the module was selected in accordance with the guidelines set by the American Society of Echocardiography [15]. This module was directed to first-time (or "naïve") learners about echocardiography and the topics therefore constituted an overview of the most basic level of competence in echocardiography (Level 1). At this introductory level, the trainee needs to obtain thorough understanding of the principles, applications and instrumentation of echocardiography as well as its limitations [15]. The trainee should also gain a thorough understanding of functional anatomy and physiology of the heart and great vessels as well as its hemodynamic properties as they relate to echocardiography [15]. Lastly, the trainee should be able to recognize common pathologies and to correlate echocardiographic findings to discoveries from other diagnostic techniques [15]. Clinical training at this level consists of interpreting 150 complete

echocardiographic examinations (M mode, 2D and Doppler) and personally performing 75 of these studies [15].

Accordingly, the content included in the module constituted an introduction to echocardiographic examination, routes and mode types; heart location and orientation in the human body; external and surface heart anatomy; image acquisition, including optimal patient position and acoustic windows and planes; standard tomographic views in echocardiography, including information about how to obtain each view and what structures are observed within each view; and a brief discussion of the assessment of heart function using 2D and Doppler echocardiography using common pathological examples (pleural and pericardial effusion, left ventricular dysfunction, right ventricular dysfunction, mitral regurgitation and aortic stenosis).

2.2. Echocardiographic videos and images

Echocardiographic videos were collected from the patient database at Kingston General Hospital. With the help of Dr. Raveen S. Pal from the Division of Cardiology, the subjects were selected to demonstrate typical normal echocardiographic findings. Echocardiographic videos of thirteen standard tomographic views (PS LAX; PS RVIT; PS SAX at the level of aortic valve, mitral valve, mid-ventricle and apex; apical 4C; apical 5C; apical 2C; apical 3C/LAX; subcostal 4C; subcostal SAX; and suprasternal) were de-identified and then exported in the form of Audio Video Interleave (.avi) files from the patient database at Kingston General Hospital. The videos were then annotated using Corel VideoStudio Pro X4 to add the required labels and the annotated videos were saved in the same format as the original videos (.avi format).

Still echocardiographic images were obtained from the de-identified .avi files using QuickTime Player. Each video was played in QuickTime Player and paused at the desired time frame. From the “Edit” tab the option “copy” was selected and then the copied content was pasted in Microsoft PowerPoint 2010 as a picture. Annotations were added to the images using the Textbox and Arrow options available in Microsoft PowerPoint 2010. The textboxes, arrows and the

echocardiographic image for each tomographic view were then “grouped” into one object using the “group” option and then saved as a .jpg image. The labels included in the annotated videos and images were anatomical directions, heart chambers, valves and their leaflets and great vessels. The still echocardiographic images for the thirteen standard tomographic views are shown in figures 4 (c), 5 (b), 6 (c), 7 (c), 8 (c), 9 (c), 10 (c), 11 (c), 12 (c), 13 (c), 14 (b), 15 (b) and 16.

2.3. Plastinated heart images

Five dissected and three untouched plastinated gross anatomical hearts were provided by the Department of Biomedical and Molecular Sciences at Queen’s University. The hearts had been plastinated using the S10 method as per the standard protocol used by the Division of Anatomy in the Department of Biomedical and Molecular Sciences at Queen’s University. Briefly, the typical main steps of silicone plastination were used: fixation, dehydration, forced impregnation with silicone plastic and curing. The untouched and dissected plastinated hearts were sectioned and trimmed, respectively, as needed, using a long sharp knife, to display different echocardiographic planes. Out of the ten planes used in the module (LAX; RVIT; SAX aortic valve, mitral valve, mid-ventricle and apex; 4C; 5C; 2C; parasternal) plastinated heart sections were prepared for only eight. The RVIT view was attempted but the heart used had abnormal rotation of the apical part of the left ventricle around the right ventricle which interfered with the view and thus was discarded. Also, due to the lack of the aortic arch on the heart specimens provided, the suprasternal long-axis of the aortic arch view could not be attempted. The prepared hearts were then photographed using a D100 Nikon Digital Camera with the help of Dr. Xiaohu Yan, a microscopist, and saved in the form of .jpg images. These images were then modified using Corel PaintShop Photo Pro X3 to add the required labels, including heart chambers, valves and their leaflets and great vessels. The edited images were then saved either as Portable Network Graphics (.png) files or .jpg files depending on the better resolution. The sectioned gross heart

photographs are shown in figures 4 (b), 6 (b), 7 (b), 8 (b), 9 (b), 10 (b), 11 (b), 12 (b) and 13 (b).

2.4. Anatomical illustrations

Illustrations were prepared using the shape and freehand drawing tools available in Microsoft PowerPoint 2010 and then saved in Joint Photographic Experts Group (.jpg) format. Three anatomical diagrams were created to demonstrate: (1) the location of the heart within the thorax in relation to the ribcage and sternum [Figure 1(b)]; (2) the pyramidal shape of the heart with its five surfaces [Figure 1(a)]; and (3) the locations of transducer placement on the anterior thoracic wall [Figure 2]. For both figures 1 (b) and 2, a photograph of an untouched plastinated heart was used instead of a drawing.

In addition, four figures were created to represent the four main standard acoustic planes with a rectangular plane passing through the hearts [Figure 3]. Moreover, similar plane images were created for every standard tomographic view of echocardiography showing the ultrasound beam in a fan shape, as it appears on an echocardiogram [Figures 4 (a), 5(a), 6(a), 7(a), 8(a), 9(a), 10(a), 11(a), 12(a), 13(a), 14(a), 15(a)]. All of the plane images were created by using the same image of the full untouched plastinated heart from an anterior view. The ultrasound beam was drawn using the freehand drawing tool and blue outline and fill colours were chosen to provide good contrast from image of heart and white background. The fans and rectangles indicating the planes were made transparent to simulate a 3D representation. For every plane image the blue fan, or rectangle, was “grouped” with the heart into one object using the “group” option and then saved as a .jpg image.

2.5. Summary tables

Summary tables were created for eight of the ten planes (LAX; RVIT; SAX aortic valve, mitral valve and mid-ventricle; 4C; 2C; parasternal) except for 5C and SAX apex because the former closely resembles 4C, and the latter only shows the edges of the ventricles. These

tables summarized the structures that can be observed within each view including the features to look for when identifying them on an echocardiographic image. The tables were created using Microsoft Word 2010 and then saved in .png format to achieve high resolution. These tables are shown in figures 17-19.

2.6. Preliminary survey: Assessment of content and images

Still labelled echocardiographic images and gross heart section images were used in the form of a 1.5 hour presentation in the month of June 2011. This was presented by a cardiologist to a group of twelve medical students who had just completed their first year of undergraduate medical studies at Queen's University. The students had no echocardiography training prior to this session and thus were considered "naïve" subjects with no previous exposure to echocardiography. However, the students had completed basic medical science courses such as normal anatomy and physiology prior to this session. A survey was administered at the end of the presentation to assess (1) the extent of content covered; (2) the quality of echocardiographic and gross anatomical images; and (3) the usefulness of anatomical specimen images in enhancing the learning experience of "naïve" echocardiography learners.

2.7. Online "IntroToEcho" Module

Based on the results obtained from the preliminary survey an online learning module was created through MEdTech with the help of Ms. Lynel Jackson, a web developer. MEdTech was chosen to create the module because it provides a secure way to deliver information to all students and faculty associated with the School of Medicine at Queen's University. It is often used by instructors at Queen's University to upload lecture notes and provide electronic learning resources to the students. The module was created as a "community", which is one of multiple ways of creating online learning modules using MEdTech, such as courses, narrated power-points and text-based interactive modules. A "community" was used because it is user-friendly,

requiring little knowledge about HTML. In addition, access to the module can be controlled (for example, during maintenance and content update) and traced (to gain an appreciation of its usefulness). The “community” was created by following the instructions available at (http://meds.queensu.ca/medtech/medtech_central_help/communities).

The anatomical information was mainly extracted from Gray’s Anatomy for Students²⁴ and echocardiography-related information from Otto’s Textbook of Clinical Echocardiography²³. The images (.png and .jpg) were uploaded to an invisible gallery on MEdTech and then linked to their respective pages in the module. The videos were also uploaded and multiple ways were attempted to allow them to loop. First, the .avi videos were uploaded by the MEdTech team to an external library. A Hypertext Markup Language (HTML) code was then created for each video by the MEdTech team to allow the videos to play in the Flash Player using MEdTech. The HTML codes that were provided were then used to upload the videos to their respective locations in the module. Although the videos were easily uploaded, they could not be looped. As a second attempt to loop the videos, the HTML codes were modified to allow the videos to play using Java Player through MEdTech but that attempt also failed. Lastly, the videos were converted to shockwave flash files (.swf) using DVDVideoSoft Free Video To Flash Converter 4.8.4.920 and uploaded to an invisible library within the module. The videos were then linked to their respective locations in the module using the “insert video” tool and the video uniform resource locator (URL). This proved to be successful.

2.8. Evaluation of the module

The module was made available to the echocardiography team, a group of cardiologists at Kingston General Hospital who are involved in echocardiography research and training. This panel of cardiologists and the associate dean of the undergraduate medical program at Queen’s University are currently evaluating the module to assess the content, image quality and usefulness of anatomical specimens.

Left atrium (LA)	Posterior to aortic root and normally has a similar antero-posterior size to the aortic root in this view
Left ventricle (LV)	Ventricular septum anteriorly and posterior LV wall
Aorta (Ao)	<u>Aortic root</u> : Sinuses of valsalva (SV); Aortic valve (AV) {right coronary cusp (RCC) anteriorly and non-coronary cusp (NCC) posteriorly (the left coronary cusp cannot be seen as it is lateral to the plane of the image)} <u>Ascending aorta (AA)</u> : Proximal 3-4 cm <u>Descending aorta (DA)</u> : In cross section posterior to the left atrium
Mitral valve (MV)	Anterior leaflet is longer than the posterior leaflet, but has a smaller annular length resulting in equal surface areas of the two leaflets
Right ventricle (RV)	A small part of the right ventricular outflow tract (RVOT) is seen anteriorly
Coronary sinus (CS)	Seen posterior to the mitral annulus in the atrio-ventricular groove

Long-axis (LAX)

Right atrium (RA)	The posterior wall of RA is seen on the right side of the image
Right ventricle (RV)	Anterior (top) and posterior (bottom) papillary muscles
Tricuspid valve (TV)	Anterior (to the right) and septal (to the left) leaflets
Coronary sinus (CS)	Seen as it enters the right atrium
Inferior vena cava (IVC)	Seen entering the right atrium inferior to CS

Right ventricular Inflow Tract (RVIT)

Figure 17 Summary tables for long-axis (LAX) and parasternal right ventricular inflow tract (PS RVIT) planes.

Aortic valve (AV)	Seen in short axis; the 3 leaflets and their associated cusps can be identified: right (R), left (L) and non-coronary (N)
Left atrium (LA)	Seen posteriorly
Inter-atrial septum	Seen between the 2 atria
Right atrium (RA)	Seen on the left hand side leading into the right ventricle
Tricuspid valve (TV)	The anterior and septal leaflets can be seen antero-medially close to the right coronary cusp of the aortic valve
Right ventricle (RV)	RVOT Seen antero-laterally adjacent to the left coronary cusp of the aortic valve
Pulmonary artery (PA)	<u>Pulmonic valve (PV)</u> : seen in long axis because the pulmonic valve is perpendicular to the aortic valve <u>Pulmonary Artery (PA)</u> : may be able to see the bifurcation into the left and right pulmonary arteries

Short-axis (Aortic valve)

Mitral valve (MV)	Seen in short axis; the anterior and posterior leaflets open fully almost to the size of the full cross sectional area of the left ventricle during diastole and close during systole
Right ventricle (RV)	Crescent-shape along the antero-medial edge of mitral valve; Cannot see the tricuspid valve because it is more basal than the mitral valve

Short-axis (Mitral valve)

Left ventricle (LV)	Circular in shape; medial and lateral papillary muscles are seen and they define the mid ventricle (one of them may be bifid giving the appearance of 3 papillary muscles)
Right ventricle (RV)	Crescent-shaped along the antero-medial edge of the left ventricle

Short-axis (Mid-ventricle)

Figure 18 Summary tables for short-axis (SAX) planes at the levels of aortic valve, mitral valve and mid-ventricle, respectively.

Left ventricle (LV)	Tapered but rounded apex
Left atrium (LA)	
Mitral valve (MV)	Anterior leaflet seen by the septum and posterior leaflet adjacent to the lateral wall attached to the lateral papillary muscle
Right ventricle (RV)	Apex is less rounded and closer to the base than the left ventricle
Right atrium (RA)	
Tricuspid valve (TV)	Annulus appears slightly more apical than the mitral annulus; septal leaflet near septum; the leaflet by free wall can either be posterior or anterior depending on the angle of the transducer
Inter-atrial septum	Parallel to the US beam so there's usually dropout (absence of signal) from the area of the fossa ovalis
Descending aorta (DA)	Lateral to the left atrium
Coronary sinus (CS)	In the atrio-ventricular groove

Four-chamber (4C)

Left ventricle (LV)	The anterior wall is seen on the right side of screen by the LA appendage and the posterior/infra-lateral wall on left side
Mitral valve (MV)	
Left atrium (LA)	LA appendage (LAA) may be seen anteriorly (right side)

Two-chamber (2C)

Aorta (Ao)	<u>Ascending aorta (AA)</u> : leading into the aortic arch <u>Aortic arch</u> : the proximal parts of the brachiocephalic, left common carotid and left subclavian arteries can be seen branching off <u>Descending aorta (DA)</u> : proximal part is seen
Superior vena cava (SVC)	Seen near the ascending aorta
Pulmonary artery (PA)	The right pulmonary artery (RPA) can be seen passing underneath the arch

Suprasternal long-axis of aortic arch

Figure 19 Summary tables for four-chamber (4C), two-chamber (2C) and suprasternal long-axis of aortic arch planes.

CHAPTER 3

RESULTS

The preliminary survey yielded 100% response from the subjects; the results about content coverage, image quality and usefulness of plastinated specimens are described below:

3.1. Content coverage

When asked about whether they found that there was enough discussion about normal echocardiographic findings, eight respondents (66.7%) agreed, three (25%) suggested more information can be provided about the ultrasound beam path and echocardiography theory and two respondents did not answer this particular question.

3.2. Image quality

The results from the survey regarding image quality and resolution are shown in Table 1. Most respondents (83.3%) found that the image resolution was good and only two (16.7%) found that it was adequate. All of the respondents found the amount of labeling and the font size to be good and most (91.7%) found the font colour comfortable for the eyes except for one respondent who found that it was straining.

	Number of respondents (#)	Percent of respondents (%)
<u>Image resolution</u>		
Good	10	83.3
Adequate	2	16.7
Poor	0	0
<u>Labeling</u>		
Excessive	0	0
Good	12	100
Little	0	0
<u>Font size</u>		
Too large	0	0
Good	12	100
Too small	0	0
<u>Font colour</u>		
Comfortable for the eyes	11	91.7
Straining for the eyes	1	8.3

Table 1 Evaluation of image quality by 12 respondents from the preliminary survey

3.3. Plastinated heart specimens

When asked about the usefulness of the plastinated anatomical specimens in understanding how to read echocardiographic images, eight respondents (66.7%) found that they helped, two (16.7%) disagreed, one (8.3%) needed more time to look at the specimens and one (8.3%) left the question blank.

3.4. Additional remarks

Lastly, when asked for suggestions to modify images or content to enhance learning two respondents suggested using echocardiographic video loops instead of still images.

3.5. Online “IntroToEcho” module on MEdTech

The IntroToEcho module can be accessed by logging in to the MEdTech Central webpage (<https://meds.queensu.ca/central/>) using a valid Queen’s username and password. The default layout in MEdTech was used for this module and is shown in figure 20. The table of contents

appears on the left-hand side of the browser window and contains eight main folders (in white boxes), which can be clicked on to retrieve their content. The folders are: overview, introduction to echocardiography, ultrasound physics, review of heart anatomy, image acquisition, standard tomographic views, assessment of heart function and credits, respectively. To make the content easier to understand, some folders contain subfolders, which appear in gray boxes in the table of contents on the left-hand side. The content contained within each subfolder can be accessed by clicking on it. When a page is selected (folder or subfolder), the content appears in the middle part of the browser window. The bar on the right-hand side is reserved for displaying information about module membership and administrative control tools. The content contained within each folder and subfolder is explained in detail below.

3.5.1. Overview

This page is the first page that appears when the user logs in to the module [Figure 20]. It provides a definition of echocardiography which is followed by the objectives of the module.

3.5.2. Introduction to echocardiography

This page contained two main sections: echocardiographic examination and modes of echocardiography [Figure 21]. Within “echocardiographic examination”, information was provided about operators, main routes of examination (TTE and TEE) and a brief comparison between TTE and TEE. Within “modes of echocardiography”, limited information was provided about different modes of echocardiographic images such as 2D and Doppler.

3.5.3. Ultrasound physics

This section contained a brief discussion of echocardiography theory and physics [Figure 22]. Ultrasound physics was explained starting from the source (probe) to the reflection (at tissue-tissue interface) and then the return of the echo to the receiver (probe).

3.5.4. Review of heart anatomy

This folder was divided into two subfolders: location and orientation of the heart and external anatomy of the heart. The two subpages can be accessed either from the table of contents (menu on the left-hand side) or from within the parent folder (Review of heart anatomy). In the parent folder a short paragraph is contained that briefly describes the content of the folder with links to the two subfolders [Figure 23]. The subfolder “location and orientation” contains information about the location of the heart within the thorax and its surface anatomy, including figure 1 (b). The pyramidal structure of the heart and its surfaces are explained under “external anatomy of the heart” along with figure 1 (a). In addition, the spatial relationship of the heart to other structures within the thorax and to the thoracic wall, were explained under external anatomy of the heart. In this subfolder, figures 24 (a-e) were also used to demonstrate the structures reflected on each surface.

3.5.5. Image acquisition

This folder contains information about procedures used for patient positioning in TTE and how to avoid respiratory motion artefact [Figure 25]. In addition, this page contains a short section on transducer positioning on the thoracic chest wall with a link to a subfolder called “acoustic windows”. This page can also be accessed from the table of contents, where it appears as a subfolder under “image acquisition”. The contents of this subfolder contain textual explanations about transducer position and motion, including figure 2 to provide additional visual representation. When transducer motion is explained, a link to the second subfolder under this parent folder was provided. This folder is called “acoustic planes” and it contains information about the four main standard acoustic planes in echocardiography. In addition to textual information, figures 3 (a-d) were also included to provide 3D visual representation of the planes.

3.5.6. Standard tomographic views

This folder contains information about standard tomographic views and image orientation [Figure 26]. To avoid overcrowding within this page, information on tomographic views was divided into six subfolders, which can be accessed from the parent folder or from the table of contents. The six subfolders were named: parasternal long-axis, parasternal short-axis, apical four-chamber, apical two-chamber, subcostal views and suprasternal views. Parasternal RVIT, apical 5C and apical 3C/LAX were covered under parasternal LAX, apical 4C and apical 2C, because the former three only involve a slight change in probe angle as compared to the latter three, respectively. The same layout was used for every view to achieve consistency and avoid confusion for the reader. A screenshot of the part about parasternal long-axis within the “parasternal long-axis” subfolder is shown in figure 27 to demonstrate this layout. At the very start of any standard tomographic view section information is provided about how to obtain the view. This is followed by a link to the summary table associated with the view, which appears in a new tab when selected. Next are the planes image and plastinated heart image associated with the view, which appear side-by-side. The sizes of these images are set to a width of 250 or 300 pixels depending on the size of the original image. At the end of the section are the looping echocardiographic flash files with a size of 500x500 pixels.

3.5.7. Assessment of heart function

This folder contains information about the use of 2D and Doppler echocardiography for the assessment of heart function [Figure 28]. Specifically, information about the use of echocardiography to assess effusions, left ventricular function, right ventricular function, mitral valve function and aortic valve function is discussed in separate subfolders within the parent folder. These five subfolders can be accessed from the table of contents on the side. Within each subfolder information is provided about the best tomographic views that can be used for assessment of the given structure, in addition to looping 500x500 pixel echocardiographic videos of

common pathological examples. The pathologies presented were pleural and pericardial effusion, global left ventricular dysfunction, right ventricular dysfunction, mitral regurgitation and aortic stenosis, respectively.

3.5.8. Credits

This page was created to give recognition to the advisors who supervised this project and to recognize contributions from the parties involved in different steps during the creation of the content and material included in the module, including the Department of Biomedical and Molecular Sciences and the Division of Cardiology.

The screenshot shows a web browser window with the URL <https://meds.queensu.ca/central/community/introtoecho>. The page title is "Introduction to Trans-thoracic Echocardiography" under the "School of Medicine" header. The main content area is titled "Echocardiography" and includes a description: "Echocardiography is an imaging technique that uses ultrasound waves to produce tomographic images (slices) of cardiac structures and to reflect blood flow." It also lists objectives for the module.

The left sidebar contains a "Table of Contents" with the following items:

- Overview
- Introduction to echocardiography
- Ultrasound physics
- Review of heart anatomy
 - Location and orientation
 - External anatomy
- Image acquisition
 - Acoustic windows
 - Acoustic planes
- Standard tomographic views
 - Parasternal Long Axis
 - Parasternal Short Axis
 - Apical 4 Chamber
 - Apical 2 Chamber
 - Subcostal views
 - Suprasternal window
- Assessment of heart function
 - Effusions
 - Right ventricular function

The right sidebar contains administrative tools under "Admin Centre" and "MEDTech Central":

- Admin Centre: Manage Community, Manage Members, Manage Pages, Community Reports
- MEDTech Central: Dashboard, Communities, Courses, Learning Events, Curriculum Search, People Search, Library, Logout
- This Community: My Membership (Hanin Abdallah, Joined: 2011-07-21), Quit This Community, View All Members, Mailing List Not Active

Table of contents

Module membership and administrative tools

Figure 20 The layout of the IntroToEcho online module as it appears on MEDTech Central. The red box indicates the table of contents in the left-hand side of the browser window. The green box indicates the page content for the selected folder or subfolder (in this figure the “overview” folder is selected). The blue box indicates the bar on the right-hand side of the browser window, where module membership and administrative tools are found.

The screenshot shows a web browser window with the URL https://meds.queensu.ca/central/community/introtoecho/introduction_to_echoecardiography. The page features a blue logo of three stylized figures and the text 'School of Medicine'. The main heading is 'Introduction to Trans-thoracic Echocardiography'. A 'Table of Contents' button is visible at the top right. The page is divided into several sections:

- Overview**: Introduction to echocardiography
- Introduction to echocardiography**: Echocardiographic examination: An echo exam is often performed by a trained physician or a cardiac sonographer under the supervision of a physician and may take anywhere from a few minutes to an hour depending on the clinical situation. There are two main routes for echocardiographic examination:
 - Trans-thoracic (TTE): through the thoracic wall
 - Trans-esophageal (TEE): through the esophageal wall
- Image acquisition**: TEE yields better quality images due to the shorter distance that the US beam has to travel to reach cardiac structures. However, because it involves the insertion of an endoscopic device it is often less favourable than TTE. Therefore, TTE is often used due to its relative ease of use and accuracy and will be the focus of the rest of this module.
- Modes of echocardiography**: Each one of the two routes of examination mentioned above can produce a variety of echocardiographic modalities/modes:
 - M-mode
 - 2D
 - 3D
 - Contrast echocardiography
 - Doppler echocardiography
- Assessment of heart function**: Anatomic 2D images and physiologic Doppler data are often used during echocardiographic interpretation to assess heart anatomy and function.

On the right side, there are three sidebar sections:

- Admin Centre**: Manage Community, Manage Members, Manage Pages, Community Reports
- MEDTech Central**: Dashboard, Communities, Courses, Learning Events, Curriculum Search, People Search, Library, Logout
- This Community**: My Membership (Hanin Abdullah, Joined: 2011-07-21), Quit This Community, View All Members, Mailing List Not Active

Figure 21 A screenshot of the “introduction to echocardiography” folder. This folder contains information about echocardiographic examination and modes of echocardiography.

Table of Contents

School of Medicine

Introduction to Trans-thoracic Echocardiography

Overview ▶ Ultrasound physics

Introduction to echocardiography

Ultrasound physics

Review of heart anatomy

Location and orientation

External anatomy

Image acquisition

Acoustic windows

Acoustic planes

Standard tomographic views

Parasternal Long Axis

Parasternal Short Axis

Apical 4 Chamber

Apical 2 Chamber

Subcostal views

Suprasternal window

Assessment of heart function

Effusions

Right ventricular function

Acoustic function

The ultrasound transducer/probe produces, transmits and receives **ultrasound (US) waves** into and from the patient's body.

Ultrasound waves are sound waves at high frequencies beyond the range that humans can hear (>20 kHz). Therefore, being sound waves, US waves consist of alternating regions of compression and rarefaction.

The speed at which US waves travel is dependent on the density of the tissue through which they pass, travelling faster in more dense tissues such as bone than in softer tissues such as blood. Tissue density determines its **acoustic impedance** which in turn determines US transmission through that tissue. When US waves hit an interface between tissues with different acoustic impedances it results in variable reflection of the ultrasound waves (echo) at the interface.

It is this **reflection of US** that gets detected by the transducer and analyzed to produce different types of echocardiographic images. The greater the return of ultrasound from an interface the brighter the area appears on an echocardiogram.

Admin Centre

- Manage Community
- Manage Members
- Manage Pages
- Community Reports

MEDTech Central

- Dashboard
- Communities
- Courses
- Learning Events
- Curriculum Search
- People Search
- Library
- Logout

This Community

My Membership

- Hanin Abdullah
- Joined: 2011-07-21

Quit This Community

View All Members

Mailing List Not Active

Figure 22 A screenshot of the “ultrasound physics” folder. This folder contains information about the production, transmission, reflection and analysis of ultrasound waves to form echocardiographic images.

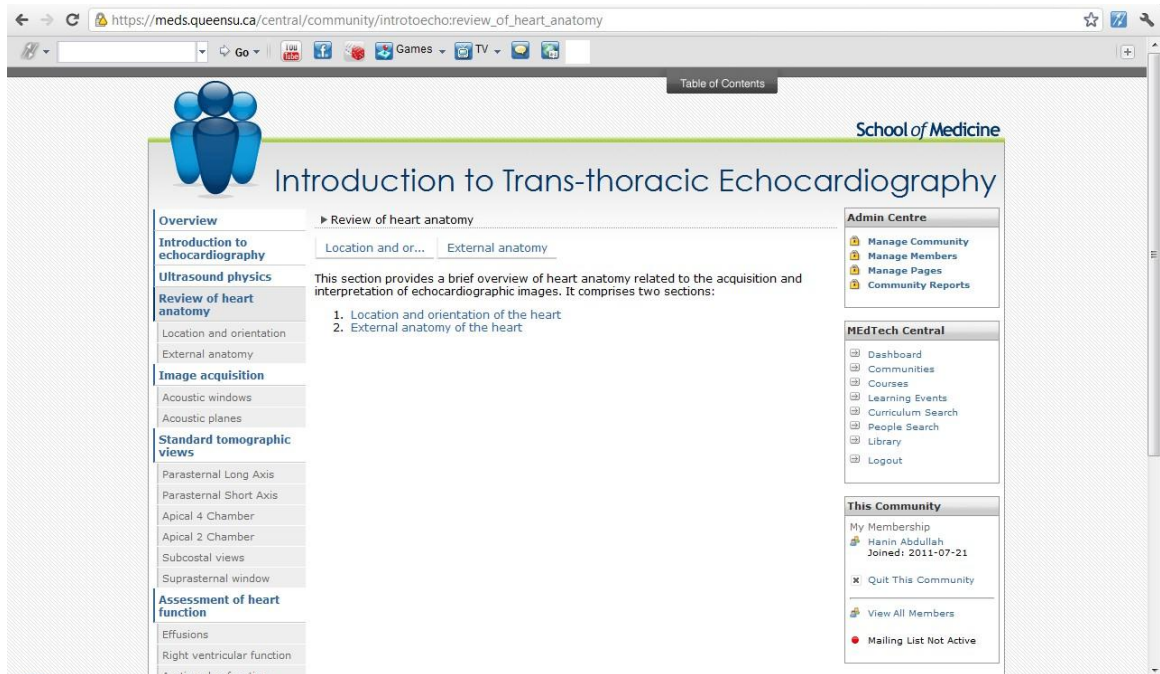
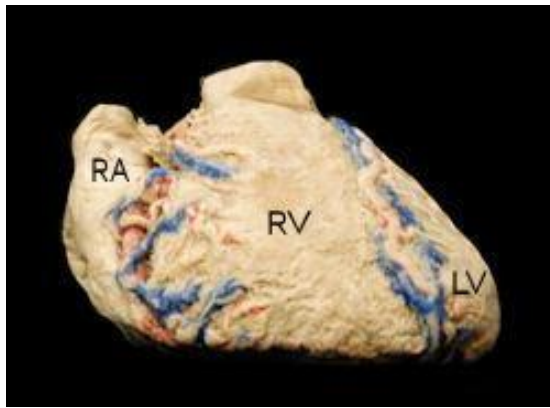
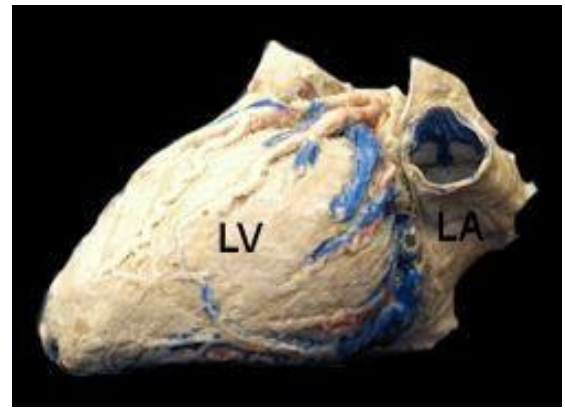


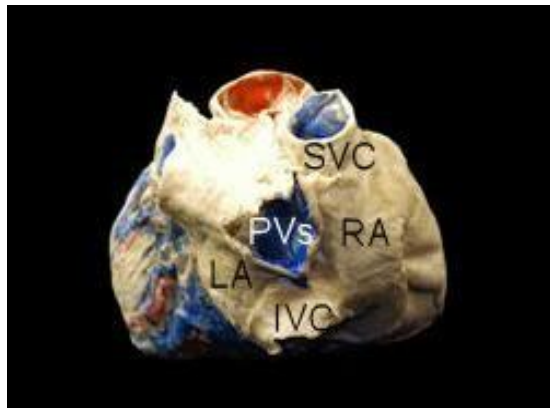Figure 23 A screenshot of the “review of heart anatomy” folder. This folder contains links to the subfolders “location and orientation of the heart” and “external anatomy of the heart”.



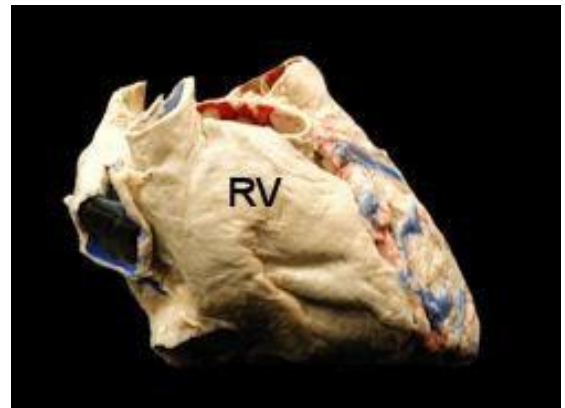(a)



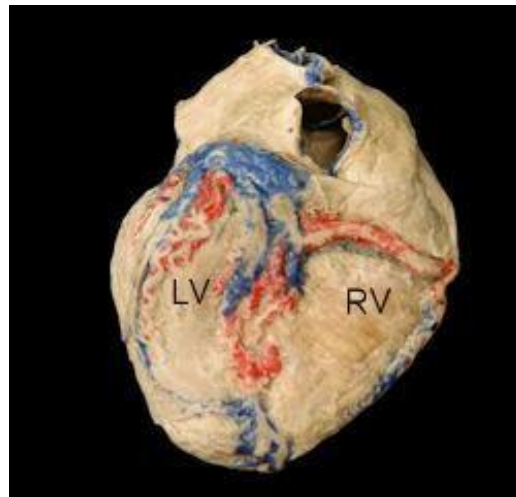
(b)



(c)



(d)



(e)

Figure 24 The five surfaces of the heart: (a) Anterior (sternocostal); (b) Left pulmonary; (c) Posterior (basal); (d) Right pulmonary; (e) Inferior (diaphragmatic). *RA* Right Atrium; *RV* Right Ventricle; *LV* Left Ventricle; *LA* Left Atrium; *SVC* Superior Vena Cava; *IVC* Inferior Vena Cava; *PVs* Pulmonary Veins.

https://meds.queensu.ca/central/community/introtoechoimage_acquisition

Table of Contents

School of Medicine

Introduction to Trans-thoracic Echocardiography

Overview ▶ Image acquisition

Introduction to echocardiography Acoustic windows Acoustic planes

Ultrasound physics

Review of heart anatomy

Location and orientation

External anatomy

Image acquisition

Acoustic windows

Acoustic planes

Standard tomographic views

Parasternal Long Axis

Parasternal Short Axis

Apical 4 Chamber

Apical 2 Chamber

Subcostal views

Suprasternal window

Assessment of heart function

Effusions

Right ventricular function

Artic valve function

Admin Centre

- Manage Community
- Manage Members
- Manage Pages
- Community Reports

MEDTech Central

- Dashboard
- Communities
- Courses
- Learning Events
- Curriculum Search
- People Search
- Library
- Logout

This Community

My Membership

Hanin Abdullah
Joined: 2011-07-21

Quit This Community

View All Members

Mailing List Not Active

Patient position:

During a TTE exam the major concerns for image acquisition are the air-filled lungs and the bony thoracic cage because they interfere with the ultrasound beam. Therefore, the patient needs to be oriented in a certain way as to limit the interference by these structures with the US beam.

The optimal patient position for a TTE exam is the left lateral decubitus position as it brings the heart close to the chest wall providing a shorter distance for the US beam to travel through. However, the patient may sometimes be asked to take a left lateral supine position if a decubitus orientation is not feasible (e.g. pregnant woman).

Structures may move in and out of focus of the image in 2D due to respiratory motion and cardiac contraction. Therefore, where applicable, the patient may be asked to hold breath to avoid "respiratory motion artefact".

Once the patient assumes position the ECG electrodes are attached to the patient's chest and a water-soluble gel is applied to where the transducer is to be placed. This is important to avoid potentially intervening air between the transducer and the chest wall.

Transducer position:

When placing the transducer onto the chest wall, the examiner often looks for spots as to avoid the bony thoracic cage (e.g. intercostal space). This helps provide optimal access of ultrasound to the heart and back. The location of the transducer on the chest wall is more commonly referred to as an "acoustic window" in TTE.

Figure 25 A screenshot of the “image acquisition” folder. This folder contains information about patient and transducer positioning as well as a link to the subfolder “acoustic windows”.

Table of Contents

School of Medicine

Introduction to Trans-thoracic Echocardiography

Overview ▶ Standard tomographic views

Parasternal Lon... Parasternal Sho... Apical 4 Chamber Apical 2 Chamber

Subcostal views Suprasternal wi...

Admin Centre

- Manage Community
- Manage Members
- Manage Pages
- Community Reports

MEDTech Central

- Dashboard
- Communities
- Courses
- Learning Events
- Curriculum Search
- People Search
- Library
- Logout

This Community

My Membership

Hanin Abdullah
Joined: 2011-07-21

Quit This Community

View All Members

Mailing List Not Active

Introduction to echocardiography

Ultrasound physics

Review of heart anatomy

Location and orientation

External anatomy

Image acquisition

Acoustic windows

Acoustic planes

Standard tomographic views

Parasternal Long Axis

Parasternal Short Axis

Apical 4 Chamber

Apical 2 Chamber

Subcostal views

Suprasternal window

Assessment of heart function

Effusions

Right ventricular function

Aortic valve function

Each individual tomographic image in echocardiography is characterized by an acoustic window (transducer position) and a plane (axis of the heart through which the US beam passes). There are 5 tomographic views that are usually used in a standard echocardiographic exam. These are:

- Parasternal Long Axis (PS LAX)
- Parasternal Short Axis (PS SAX)
- Apical 4 Chamber (Apical 4C)
- Apical 2 Chamber (Apical 2C)
- Subcostal

In specific cases other types of tomographic views may be used to allow better examination of the heart. Some of these views will be mentioned throughout the module, where applicable.

Image orientation:

Most adult echocardiography images in most labs follow the guidelines put together by the American Society of Echocardiography (ASE). The ASE recommends that the image is oriented such that the top-most part of the image is the part of the heart that is closest to the transducer on the patient (narrow portion of the cone shaped image). In addition, in short axis and four chamber views the right (medial) side is shown on the left hand side as if looking at the heart from the apex up onto the base (like CT). Lastly, in long axis the the basal structures appear on the right hand side as if looking at the heart from the left side of the body towards the right side.

Figure 26 A screenshot of the “standard tomographic views” folder. This folder contains information about standard tomographic views in transthoracic echocardiography and image orientation in echocardiography. Links to subfolders parasternal long-axis, parasternal short-axis, apical 4 chamber, apical 2 chamber, subcostal views and suprasternal window are also provided.

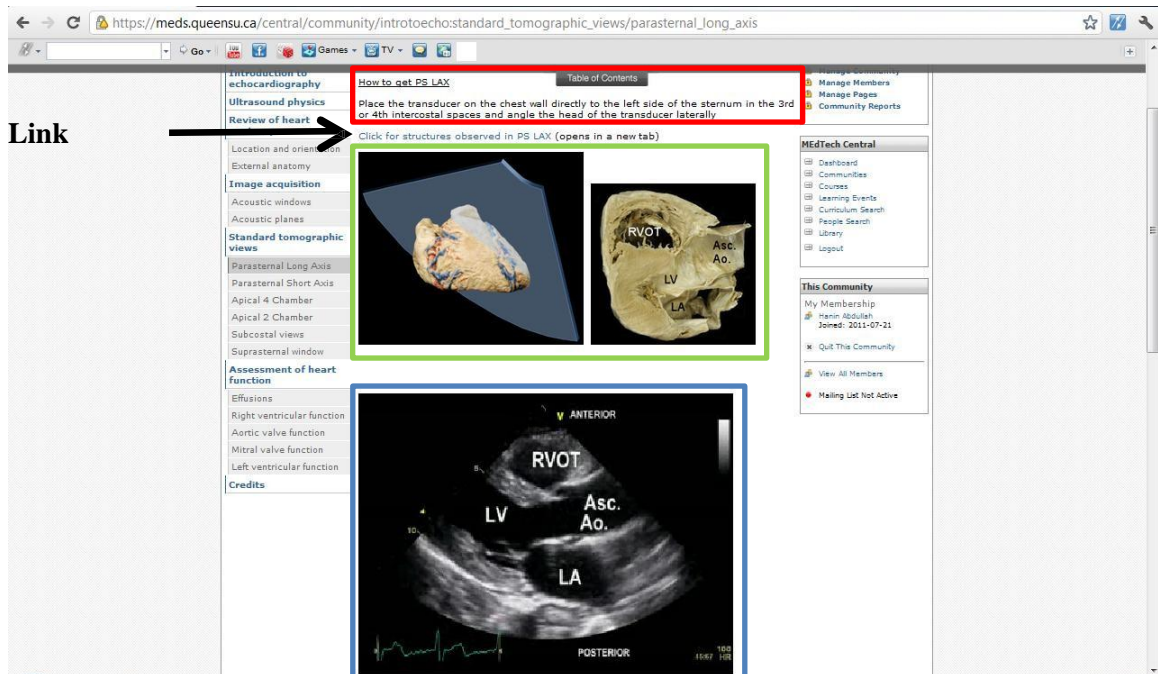


Figure 27 A screenshot of the top portion of the “parasternal long-axis” subfolder. This demonstrates the layout that was used for all of the standard tomographic views discussed in the module. At the top there is information about how to obtain the view (in red box), followed by a link to summary tables (link). Next are the plane image and sliced heart image associated with the view (in green box), followed by the looping echocardiographic flash file (in blue box).

The screenshot displays a web browser window with the URL https://meds.queensu.ca/central/community/introtoecho:assessment_of_heart_function. The page header includes the School of Medicine logo and a 'Table of Contents' link. The main content area is titled 'Introduction to Trans-thoracic Echocardiography' and is organized into a sidebar and a main text area. The sidebar lists various topics under 'Assessment of heart function', including 'Effusions', 'Left ventricula...', 'Right ventricul...', 'Mitral valve fu...', and 'Aortic valve fu...'. The main text area provides detailed information on '2D Echocardiography' and 'Doppler echocardiography'. The '2D Echocardiography' section explains that due to the heart's shape and orientation, different parts of the same structure may appear in various views, making specific views more useful for assessment. The 'Doppler echocardiography' section describes the Doppler Effect, where the frequency of an echo is higher than the original sound if the object is moving towards the listener, and lower if moving away. It also notes that Doppler echocardiography is based on the change in frequency of ultrasound as a result of backscatter by moving blood cells. The right sidebar contains navigation links for 'Admin Centre' (Manage Community, Manage Members, Manage Pages, Community Reports), 'MEDTech Central' (Dashboard, Communities, Courses, Learning Events, Curriculum Search, People Search, Library, Logout), and 'This Community' (My Membership: Hanin Abdullah, Joined: 2011-07-21, View All Members, Mailing List Not Active).

Figure 28 A screenshot of the “assessment of heart function” folder. This folder contains information about the assessment of heart function using 2D and Doppler echocardiography.

CHAPTER 4

DISCUSSION

Due to the numerous advantages of echocardiography over other cardiovascular imaging techniques, it has been increasingly used. As a result, echocardiography training is being provided to more postgraduate medical trainees and even to undergraduate medical students. Due to the numerous advantages of online learning multiple electronic learning resources have been developed that are devoted to echocardiography. However, there is not a single tool that is designed to provide the “naïve” learner with sufficient, but not too overwhelming, information about echocardiography. This online learning tool was developed to introduce “naïve” echocardiography learners at Queen’s University to the basic principles of echocardiography and echocardiographic image acquisition and interpretation. The preliminary survey administered prior to the development of the module provided useful feedback about what a naïve learner would like to be exposed to on their first encounter with echocardiography.

4.1. Content

The guidelines set out by ASE were used as a basic structure for the selection of the content for the IntroToEcho module. The content of the module was chosen to provide an overview of what the learner should achieve by the end of their basic level training in echocardiography, including an introduction to echocardiography theory and use, summary of heart anatomy and physiology and information about image acquisition and interpretation. The focus of the IntroToEcho module was mainly on 2D and Doppler echocardiography because these are the most commonly used echocardiography modes for medical diagnosis as they display the anatomy of the heart in a way that is familiar to the reader [28]. In addition, the focus of the module was on TTE because it is the most commonly used route for echocardiographic examination [25] and it is also

usually learned prior to TEE training [15].

Based on the results obtained from the twelve first year medical students, the amount of information presented was appropriate for their limited knowledge in echocardiography. The suggestion by the three respondents from the preliminary survey about the discussion of ultrasound beam path has been incorporated in the ultrasound physics section of the module describing briefly the path of the ultrasound wave. This information may help learners better understand the theory by which the echocardiographic images form and thus may aid in interpretation [29].

4.2. Image quality

Based on the results revealed by the survey regarding image resolution, labeling and font size and colour, all of the images were retained in the same format when uploaded to the online module. The images were either saved in .jpg or .png formats because of the relatively high resolution. Plastinated section images and echocardiographic images were labelled fairly extensively to help first-time learners and the labelling was always in black and white to avoid bright colours such as yellow and red which may appear different on different devices and may be straining on the eyes. It was suggested by a couple of respondents to the preliminary survey to replace the still echocardiographic images with video loops to simulate the real experience of real-time echocardiographic examination and reading. This is important because images cannot display motion and thus will not help the students recognize normal versus abnormal wall motion. In addition, valve function is also best represented in videos as the closing and opening of valves can be appreciated using a video rather than an image.

4.3. Plastinated heart specimens

Plastinated anatomical sections can be useful for learning echocardiographic anatomy by allowing the students to be able to gain an appreciation of the great anatomic detail and spatial

relationship of the anatomical structures to one another [28]. The anatomical specimen images precede the echocardiographic images in the module to allow the learner to familiarize themselves with the cardiac structures and the plane of image acquisition. This was thought to make it easier for the learner to then put the echocardiographic images into the already-known gross anatomical perspective. Most of the respondents from the preliminary survey found the specimen images useful for understanding echocardiographic anatomy. However, one of the respondents found that there was not enough time during the one and a half hour presentation to examine the images carefully and put them into perspective. This issue of time constraint can be eliminated by making the images and content available online to allow the students to learn at their own pace.

4.4. Online “IntroToEcho” module

An online learning resource was created due to the multiple advantages that online learning has over other methods of learning, such as didactic. A good online resource is easily accessible and available to the learner to allow learner-driven learning pace and time. Also, it allows the use of interactive tools, such as linking pages, to allow easy navigation. Online modules are easy to update and distribute and allow the incorporation of multiple modalities of learning. [22-24]

The “IntroToEcho” module is easily accessible through the password-secured MEdTech Central webpage (<https://meds.queensu.ca/central/>) using a valid Queen’s username and password. This website is familiar to the students as this is where faculty and instructors often post lecture notes and online resources for the students. Therefore, MEdTech provides a convenient location for access by the students. In addition, being password-protected, MEdTech allows uploading deidentified patient echocardiographic videos and donor heart specimen images minimize confidentiality and copyright concerns.

The module is always available so the learners can easily access the module at any time and for however long they wish. This allows for a self-driven pace of learning without time or

location constraints that are often associated with didactic teaching methods. In addition, the layout of the module limits the unused space to allow efficient use of learning space in the module. As well, the interactive features within the module allow for easy navigation. For example, the learner can skip pages by simply selecting the desired page from the table of content menu available on the left-hand side of the screen. This allows the learner to take breaks rather than have to go through the entire module all at once, allowing flexibility.

During preparation of the online module multiple methods of learning were incorporated to complement multiple learning styles. For example, for every standard view, echocardiographic video loops were used in conjunction with anatomical illustrations, plastinated heart images, text and summary tables. The presence of textual information in this module makes it a more useful learning tool for first-time learners than many of the other echocardiography modules available online, including the Yale Atlas of Echocardiography. Also, the summary tables provide a more user-friendly and straight-forward way of presenting information. Having the tables appear in a new resizable window when selected may prove more useful than appearing in a new tab. However, this was a limitation of MEdTech that could not be overcome.

As a result of the user-friendliness of the module and its ease of access and availability, it may prove useful not only to the postgraduate and undergraduate medical students but also to the physicians who are already in practice who wish to learn about echocardiography as part of their continued medical education. This latter group often cannot have extensive training such as is offered by fellowship programs due to their full-time responsibilities. This module can prove useful for this group by providing the introductory information in an easy-to-access online resource.

4.5. Future considerations

It is the ultimate goal of the School of Medicine at Queen's University to integrate ultrasound into the undergraduate medical curriculum. This module may prove useful at introducing cardiac

ultrasound to the medical students during their anatomy and physiology courses in first year and as an enhancement to the cardiovascular block in second year. It is important to obtain feedback from the students who use this module to evaluate the effectiveness of learning about ultrasound.

Moreover, the material presented in this module will also be made available using SGAHIC, a library of basic science and clinical resources created by Dr. Stephen Pang from the Department of Biomedical and Molecular Sciences at Queen's University. This rich learning tool is available to all of the students and faculty associated with Queen's University. Uploading learning material from the module to this tool may prove useful for other students registered in courses in anatomy and physiology, such as life sciences and nursing students. It may provide an engaging and interesting way of learning about the cardiovascular system.

4.6. Conclusion

The online module was created using MEdTech, which provides the best means of distribution to students and faculty in the School of Medicine at Queen's University. Undergraduate medical students found the content and the material used in the module very useful at enhancing their learning about cardiovascular anatomy and physiology as it relates to echocardiography. Also, based on assessments from practicing cardiologists at Kingston General Hospital, the module was found to be very useful for introduction to echocardiography with a great potential to be useful for postgraduate medical trainees in echocardiography.

REFERENCES

1. Health Concerns: Heart and Stroke by Health Canada. December 2011. Available from: <http://hc-sc.gc.ca/hc-ps/dc-ma/heart-coeur-eng.php>.
2. Deaths so far this year by the Centre for Chronic Disease Prevention and Control. December 2011. Available from: <http://www.phac-aspc.gc.ca/ccdpc-cpcmc/index-eng.php>.
3. 2009 Tracking Heart Disease and Stroke in Canada by the Public Health Agency of Canada. December 2011. Available from: <http://www.phac-aspc.gc.ca/publicat/2009/cvd-avc/report-rapport-eng.php>.
4. Roelandt JR. Ultrasound stethoscopy. *European journal of internal medicine*. 2004;15(6):337-47. Epub 2004/11/04.
5. Brunner M, Moeslinger T, Spieckermann PG. Echocardiography for teaching cardiac physiology in practical student courses. *The American journal of physiology*. 1995;268(6 Pt 3):S2-9. Epub 1995/06/01.
6. Moore CL, Copel JA. Point-of-care ultrasonography. *The New England journal of medicine*. 2011;364(8):749-57. Epub 2011/02/25.
7. Shapiro RS, Ko PK, Jacobson S. A pilot project to study the use of ultrasonography for teaching physical examination to medical students. *Computers in biology and medicine*. 2002;32(6):403-9. Epub 2002/10/03.
8. Hoppmann RA, Rao VV, Poston MB, Howe DB, Hunt PS, Fowler SD, et al. An integrated ultrasound curriculum (iUSC) for medical students: 4-year experience. *Critical ultrasound journal*. 2011;3(1):1-12. Epub 2011/04/26.
9. Wittich CM, Montgomery SC, Neben MA, Palmer BA, Callahan MJ, Seward JB, et al. Teaching cardiovascular anatomy to medical students by using a handheld ultrasound

- device. JAMA : the journal of the American Medical Association. 2002;288(9):1062-3. Epub 2002/09/11.
10. Bruce CJ, Spittell PC, Montgomery SC, Bailey KR, Tajik AJ, Seward JB. Personal ultrasound imager: abdominal aortic aneurysm screening. Journal of the American Society of Echocardiography : official publication of the American Society of Echocardiography. 2000;13(7):674-9. Epub 2000/07/11.
 11. Kimura BJ, Bocchicchio M, Willis CL, Demaria AN. Screening cardiac ultrasonographic examination in patients with suspected cardiac disease in the emergency department. American heart journal. 2001;142(2):324-30. Epub 2001/08/02.
 12. Syperda VA, Trivedi PN, Melo LC, Freeman ML, Ledermann EJ, Smith TM, et al. Ultrasonography in preclinical education: a pilot study. The Journal of the American Osteopathic Association. 2008;108(10):601-5. Epub 2008/10/25.
 13. Dubosh NM, Kman N, Bahner D. Ultrasound interest group: a novel method of expanding ultrasound education in medical school. Critical ultrasound journal [Internet]. 2011; 3:[131-4 pp.].
 14. Demographics of postgraduate medical trainees. Postgraduate Medical Education Office at Queen's University; 2011.
 15. Ryan T, Armstrong WF, Khandheria BK, American Society of E. Task force 4: training in echocardiography endorsed by the American Society of Echocardiography. Journal of the American College of Cardiology. 2008;51(3):361-7. Epub 2008/01/22.
 16. Vignon P, Mucke F, Bellec F, Marin B, Croce J, Brouqui T, et al. Basic critical care echocardiography: validation of a curriculum dedicated to noncardiologist residents. Critical care medicine. 2011;39(4):636-42. Epub 2011/01/12.
 17. Gogalniceanu P, Sheena Y, Kashef E, Purkayastha S, Darzi A, Paraskeva P. Is basic emergency ultrasound training feasible as part of standard undergraduate medical education? Journal of surgical education. 2010;67(3):152-6. Epub 2010/07/16.

18. Tshibwabwa ET, Groves HM. Integration of ultrasound in the education programme in anatomy. *Medical education*. 2005;39(11):1148. Epub 2005/11/03.
19. Rao S, van Holsbeeck L, Musial JL, Parker A, Bouffard JA, Bridge P, et al. A pilot study of comprehensive ultrasound education at the Wayne State University School of Medicine: a pioneer year review. *Journal of ultrasound in medicine : official journal of the American Institute of Ultrasound in Medicine*. 2008;27(5):745-9. Epub 2008/04/22.
20. Barloon TJ, Brown BP, Abu-Yousef MM, Ferguson KJ, Schweiger GD, Erkonen WE, et al. Teaching physical examination of the adult liver with use of real-time sonography. *Academic radiology*. 1998;5(2):101-3. Epub 1998/03/04.
21. Butter J, Grant TH, Egan M, Kaye M, Wayne DB, Carrion-Carire V, et al. Does ultrasound training boost Year 1 medical student competence and confidence when learning abdominal examination? *Medical education*. 2007;41(9):843-8. Epub 2007/08/19.
22. Greenhalgh T. Computer assisted learning in undergraduate medical education. *Bmj*. 2001;322(7277):40-4. Epub 2001/01/05.
23. Ruiz JG, Mintzer MJ, Leipzig RM. The impact of E-learning in medical education. *Academic medicine : journal of the Association of American Medical Colleges*. 2006;81(3):207-12. Epub 2006/02/28.
24. Wong G, Greenhalgh T, Pawson R. Internet-based medical education: a realist review of what works, for whom and in what circumstances. *BMC medical education*. 2010;10:12. Epub 2010/02/04.
25. Otto CM. *Textbook of clinical echocardiography*. 4th ed. Philadelphia: Saunders/Elsevier; 2009. xv, 519 p. p.
26. Drake RL, Vogl W, Mitchell AWM. *Gray's Anatomy for Students*. Philadelphia: Elsevier/Churchill Livingstone; 2005.
27. Pal RS of Kingston General Hospital. *Useful tomographic views*. 2011.

28. Gomez A, Del Palacio JF, Latorre R, Henry RW, Sarria R, Albors OL. Plastinated Heart Slices Aid Echocardiographic Interpretation in the Dog. *Veterinary radiology & ultrasound: the official journal of the American College of Veterinary Radiology and the International Veterinary Radiology Association*. 2011. Epub 2011/11/19.
29. Yoo MC, Villegas L, Jones DB. Basic ultrasound curriculum for medical students: validation of content and phantom. *Journal of laparoendoscopic & advanced surgical techniques Part A*. 2004;14(6):374-9. Epub 2005/02/03.

APPENDIX A

Cardiology Images

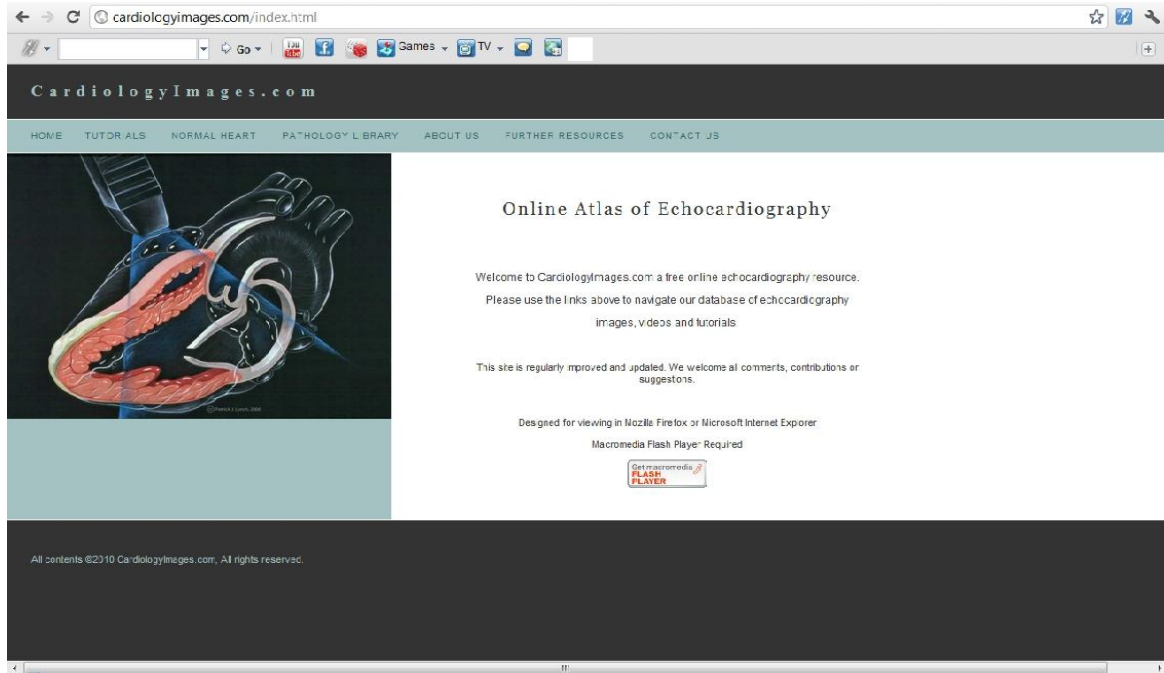


Figure A Cardiology Images: <http://cardiologyimages.com/index.html>.

Organization:

- Tutorial: A 9:29 minute long introductory presentation about echocardiography in emergency medicine. This presentation starts by providing a definition about echocardiography followed by a discussion about image orientation and probe placement. The speaker then provides thorough explanation about four standard tomographic views (subcostal four-chamber, parasternal long-axis, parasternal short-axis and apical four-chamber). The remainder (almost half) of the video focusses on recognizing common pathologies in emergency medicine, such as pericardial effusion.

- Normal heart: Drop down menus named after the acoustic windows with their associated tomographic views in TEE and TTE. However, some of the views could not be accessed due to an error indicating missing content.
- Pathology library: Extensive list of pathologies that can be assessed using echocardiography categorized by aorta, atrium and atrial septum, cardiomyopathies, congenital heart disease, infective, mitral valve, normal variants, pericardial disease, pulmonic and pulmonary valve, the right heart, tricuspid valve, tumours and extrinsic masses, ventricular septum, thromboembolic and miscellaneous/medical. However, information and examples were provided for only a few of them.
- About us: information about affiliation, contribution and support to the resource.
- Further resources: links to external resources such as free online echocardiography resources, professional accreditation organizations, echocardiography hands-on training courses, international jobs in echocardiography and subscription-based echocardiography training websites
- Contact us: contact email address

Image and video quality: variable from very poor with very low resolution, to very good with high resolution.

Explanatory text: No information in normal views and no to very limited information about pathological videos.

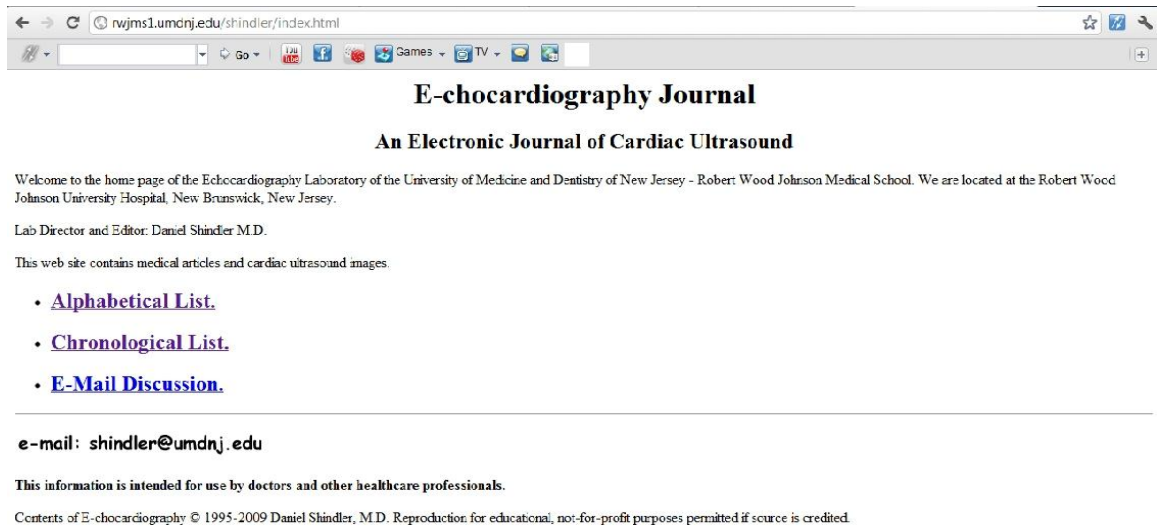
Labelling: no labelling on normal or pathological videos and images

Use of space: good (content covers a sufficient area of the browser window but there is also little unused space that limits overcrowding)

Target audience: Postgraduate medical trainees in emergency medicine

Update: unknown

E-chocardiography journal



Welcome to the home page of the Echocardiography Laboratory of the University of Medicine and Dentistry of New Jersey - Robert Wood Johnson Medical School. We are located at the Robert Wood Johnson University Hospital, New Brunswick, New Jersey.

Lab Director and Editor: Daniel Shindler MD.

This web site contains medical articles and cardiac ultrasound images.

- [Alphabetical List.](#)
- [Chronological List.](#)
- [E-Mail Discussion.](#)

e-mail: shindler@umdj.edu

This information is intended for use by doctors and other healthcare professionals.

Contents of E-chocardiography © 1995-2009 Daniel Shindler, M.D. Reproduction for educational, not-for-profit purposes permitted if source is credited.

Figure B E-chocardiography Journal: <http://rwjms1.umdj.edu/shindler/index.html>.

Organization: Contains a list of journal articles that can either be viewed by chronological or alphabetical order. This resource also contains a list of the echocardiographic images used in the paper articles organized by alphabetical order of the condition displayed.

Image and video quality: Image quality was variable, depending on the source of the image. No videos were provided.

Explanatory text: Some images had links to external resources that provide extra information about the condition displayed.

Labelling: minimal labelling, depending on the source of the image

Use of space: poor (most of the browser window is dedicated to content of the website and about a third is white space)

Target audience: The resource seems targeted to practicing physicians or trainees in advanced levels of training in echocardiography in echocardiography who would like to obtain information about specific conditions.

Update: Last updated in 2009

CTNS (Cardiothoracic Surgery Network) Echocardiography

Echocardiography

Go to the Digital Echocardiography Library

View the TSDA Transesophageal Echocardiography Review

[Audio lecture](#) [Exam questions](#) [Reference Articles](#) [Residents' section](#)

View TSDA Curriculum Online for this topic

1. High frequency ultrasound = 2.0 - 7.5 MHz
 - Adults = 2.0 - 2.5 MHz
 - Pediatric = 3.0 - 5.0 MHz
 - TEE = 3.5 - 7.5 MHz
2. Standard Transducer Position:
 - Trans-thoracic - long and 90° short axis
 - Parasternal - long and short
 - Apical
 - Subcostal - 4 chamber and ventricular septum
 - Suprasternal
 - Transesophageal

Figure C CTNS (Cardiothoracic Surgery Network) Echocardiography: <http://www.ctsnet.org/residents/ctsn/archives/not04.html>.

Organization:

- High frequency ultrasound: very limited information about different ultrasound frequencies used for different patient populations (adult vs. pediatric)
- Standard transducer position: A collection of images related to acoustic windows and planes. The two terms were not defined and there was no explanation about how the windows and planes fit together to give the tomographic views.
- Doppler Effect: A brief description of the Doppler Effect and how it can be used in echocardiography. This information was presented in point-form.
- Colour Flow Imaging: A brief description of how to interpret colour flow echocardiographic images, in point-form.

- Hemodynamic assessment by Doppler: a collection of physical equations and titles of physical principles related to the use of Doppler to assess the hemodynamic properties of the heart.
- Typical 2D ECHO patterns: A collection of normal and pathological echocardiographic images and videos. Four normal images, and their associated videos, and twenty pathological images, and their associated videos, are presented. The videos could not be played in the browser and they had to be saved to the computer device to be viewed.
- Intraoperative: naming uses for echocardiography during surgery

Image and video quality: Images were very small in size and the labels, if present, were hard to see. The videos did not play in the browser; rather they should be saved to the computer device to be viewed. The videos also lacked labels.

Explanatory text: very minimal, if any.

Labelling: images were labelled but the labels were difficult to see due to the small size of the images. The videos were not labelled.

Use of space: very poor (half of the browser window is dedicated to content of the website and the other half is white space)

Target audience: could not be determined

Update: last revised in 2002

ECHOinContext

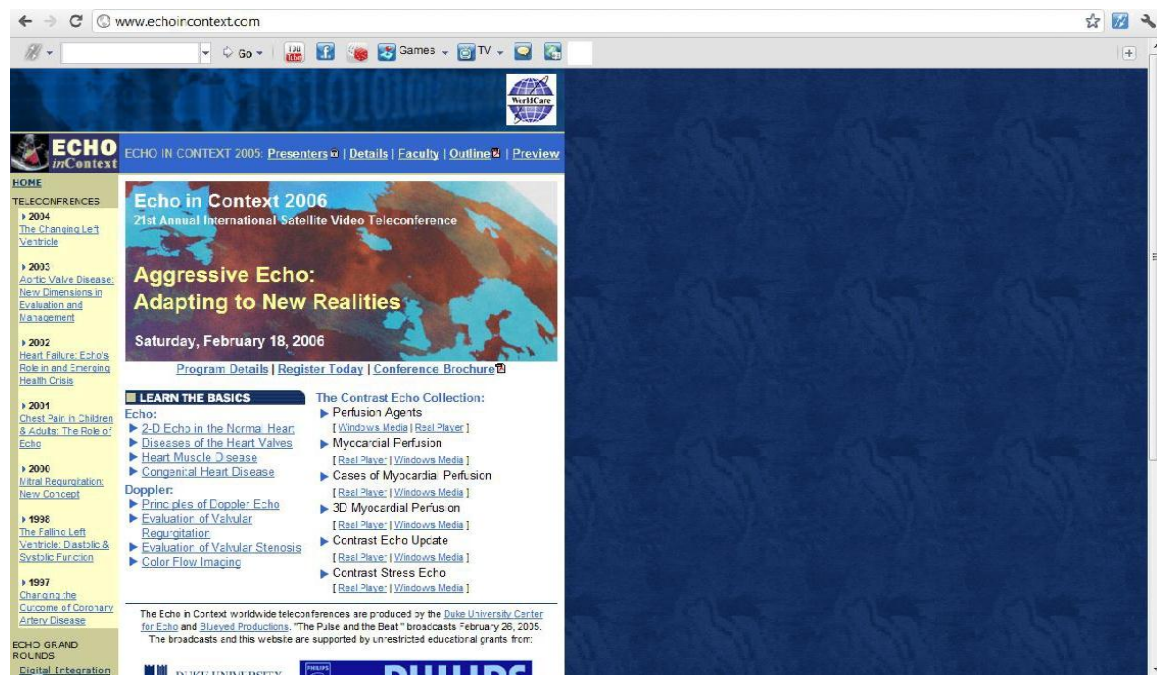


Figure D ECHOinContext: <http://www.echoincontext.com/>.

Organization:

- Echo
 - 2-D echo in the normal heart: information about the basics of echocardiography including instrumentation, how the system works and image formation, patient position, acoustic windows and planes and parasternal long-axis and short-axis views.
 - Diseases of the heart valves: extensive information about how to assess valve function using echocardiography with numerous thoroughly-explained valve pathologies
 - Heart muscle disease: extensive information about how to assess heart muscle using echocardiography with numerous thoroughly-explained related pathologies

- Congenital heart disease: extensive information about how to assess congenital heart disease using echocardiography with numerous thoroughly-explained related pathologies
- Doppler
 - Principles of Doppler echo: Comprehensive explanations about the physics behind the Doppler Effect, application of the Doppler Effect in ultrasound, the use of Doppler control and Doppler ultrasound instrumentation.
 - Evaluation of valvular regurgitation: extensive information about use of Doppler echocardiography to evaluate valvular regurgitation
 - Evaluation of valvular stenosis: extensive information about use of Doppler echocardiography to evaluate valvular stenosis
 - Color flow imaging: extensive information about formation, use and interpretation of colour flow imaging in echocardiography

Image and video quality: The images are small but can be viewed larger in a new window when clicked. There are no videos in this resource.

Explanatory text: rich in explanations for most of the topics covered

Labelling: no labelling

Use of space: very poor (half of the browser window is dedicated to content of the website and the other half is blue space)

Target audience: Due to the extensive content coverage about instrumentation and ultrasound theory it seems to be directed to novice learners who have had previous exposure to echocardiography

Update: last updated in 2000

Echocardiology

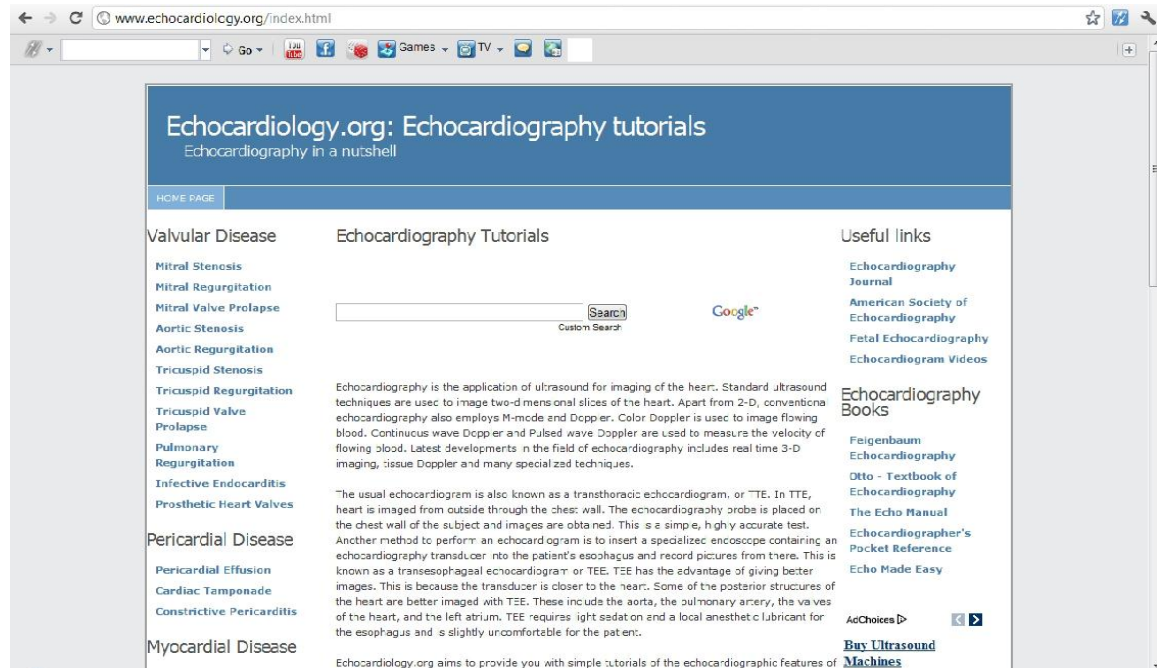


Figure E Echocardiology: <http://www.echocardiology.org/index.html>.

Organization:

- Contains a short overview of echocardiography including mode and routes of examination.
- A library of pathologies categorised by valvular disease, pericardial disease, myocardial disease, congenital disease and miscellaneous. For every condition there is extensive information about the etiology, signs and symptoms, complications, findings on different modalities of imaging and treatment.

Image and video quality: There are no videos or images in this module

Explanatory text: content presented in point-form

Labelling: not applicable (no images or videos)

Target audience: due to the extensive clinically based information this resource seems to be directed to learners who have gained sufficient knowledge about normal echocardiography and who are now learning about assessment of heart pathologies using ultrasound.

Update: last updated in 2006

The Yale Atlas of Echocardiography

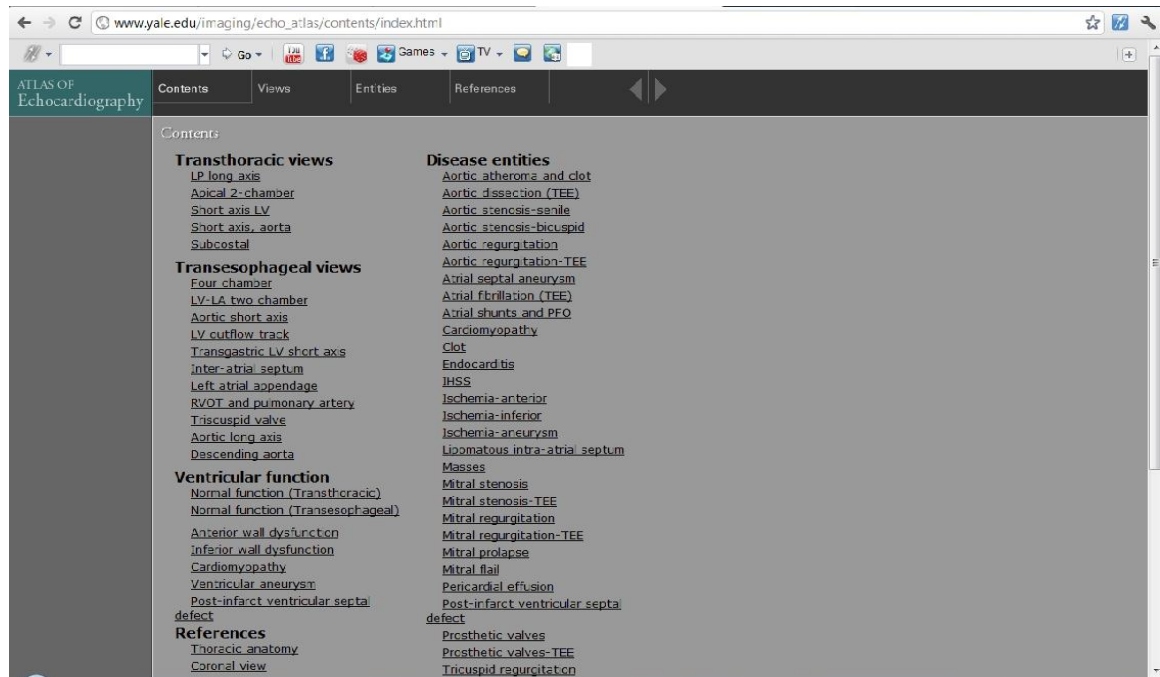


Figure F The Yale Atlas of Echocardiography:
http://www.yale.edu/imaging/echo_atlas/contents/index.html.

Organization:

- **Transthoracic views:** a collection of labelled echocardiographic images and video loops as well as drawings for parasternal long-axis, apical two-chamber, short-axis left ventricle, short-axis aorta, four-chamber and subcostal. For every view a short paragraph is included that describes some of the structures seen.
- **Transesophageal views:** content within this page could not be accessed
- **Ventricular function:** contains information about certain pathologies that are also described under entities. A paragraph, if present, contains information about the etiology and pathophysiology of these entities.
- **References:** A collection of anatomical illustrations. Some of the images were not able to load because they had been removed.

- Disease entities: contains information about certain pathologies that are also described under entities. A paragraph, if present, contains information about the etiology and pathophysiology of these entities.

Image and video quality: anatomical illustrations and echocardiographic images and videos were of good quality. The videos were typical representations of their respective conditions.

Explanatory text: minimal information, if provided, included a brief description of some structures observed within certain views and etiology of conditions.

Labelling: sufficient labelling

Target audience: Due to the amount of information provided this resource seemed to target novice learners who have had some exposure to echocardiography

Update: last update could not be determined